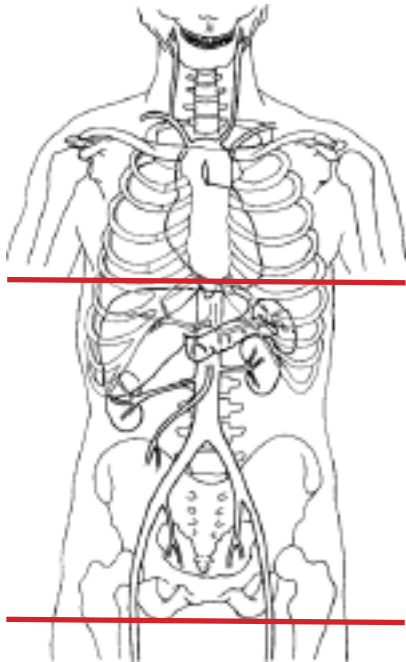


CT Abdomen/Pelvis WITHOUT Contrast - STONE PROTOCOL



Pt Position	Supine
Contrast	NA
Injection Rate	NA
Respiration	Breath - hold
Volume	Appropriate to achieve images as specified in the following tables
Aquisition Specs	- Dome of diaphragm to ischial tuberosity must have indications such as FLANK PAIN or POSITIVE HEMATURIA Otherwise, must be cleared by radiologist prior to exam

Topogram (Scout)				
PLANE	ALGORITHM	THICKNESS	DFOV	
Axial	Abdomen	5.0 mm	pt largest + 4cm	
Coronal	Abdomen	5.0 mm	pt largest + 4cm	Recon
Sagittal	Abdomen	5.0 mm	pt largest + 4cm	Recon

NOTES:

- LMP on pts of child-bearing age
- Shield children when possible