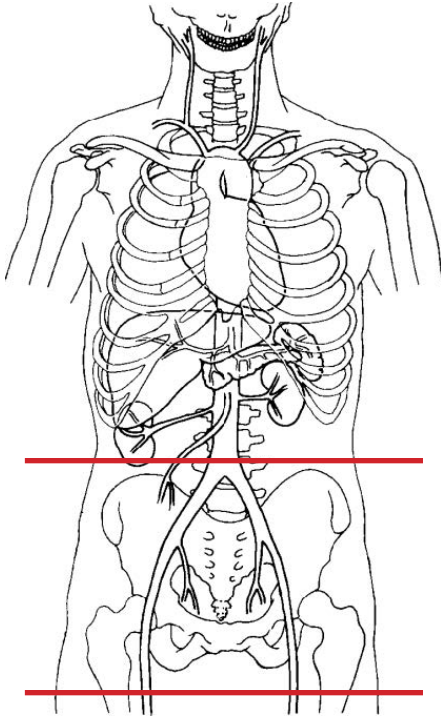


CT Bony Pelvis Without IV Contrast



Pt Position	Supine
Contrast	None
Injection Rate	N/A
Respiration	N/A
Volume Acquisition Specs	Appropriate to achieve images as specified in the following tables Small FOV Iliac crest to lesser trochanter

PLANE	ALGORITHM	THICKNESS	DFOV	
Axial	Bone	3.0 mm	pt size + 4cm	
Axial	Soft Tissue	3.0 mm	pt size + 4cm	
Coronal	Bone	3.0 mm	pt size + 4cm	reformat
Sagittal	Bone	3.0 mm	pt size + 4cm	reformat

NOTES:

- LMP on pts of child-bearing age
- Shield children when possible