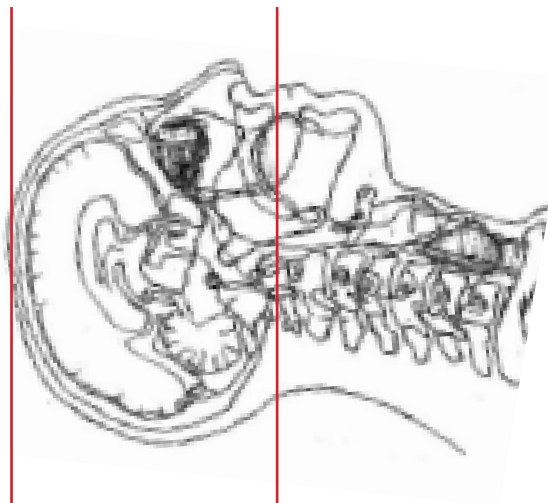
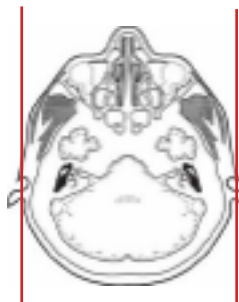
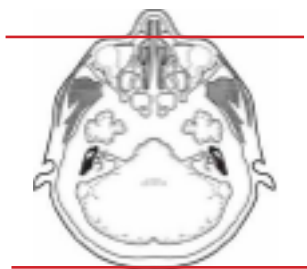


### CT Brain Without IV Contrast



<b>Pt Position</b>	Supine IOML perpendicular to table
<b>Contrast</b>	None
<b>Injection Rate</b>	N/A
<b>Respiration</b>	Breath - hold
<b>Volume Acquisition Specs</b>	Appropriate to achieve images as specified in the following tables Head SFOV



PLANE	ALGORITHM	THICKNESS	DFOV
Axial	Brain	5.0 mm	approx 220 mm
Axial	Bone	5.0 mm	approx 220 mm
* Coronal	Brain	5.0 mm	approx 220 mm
* Sagittal	Brain	5.0 mm	approx 220 mm

\* Reformat

**NOTES:**

\*IOML perpendicular is optimal for potential reconstruction