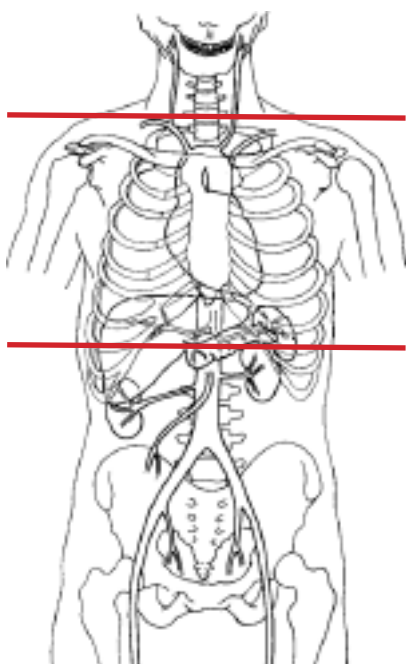


### CT Chest Lung Screening w/o Contrast



<b>Pt Position</b>	Supine
<b>Contrast</b>	None
<b>Injection Rate</b>	N/A
<b>Respiration</b>	Breath - hold
<b>Aquisition Specs</b>	Appropriate to achieve images as specified in the following table
	- thoracic outlet to bottom of lungs
<b>Indications</b>	Patient aged 55 – 74 $\geq 30$ pack year history of smoking Smoking cessation < 15 years Lung cancer screening

Topogram (Scout) Supine					
PLANE	ALGORITHM	**THICKNESS	**INTERVAL	DFOV	
Axial	Mediastinum & Lung	1.25 mm	1.25 mm	pt largest + 4cm	
Sagittal	MPR	0.625 mm	0.625 mm	pt largest + 4cm	reformats
Coronal	MPR	0.625 mm	0.625 mm	pt largest + 4cm	reformats
Axial	MIP	8 mm	3 mm	pt largest + 4cm	
<b>** Preferred slice thickness &amp; interval. Minimum 3/3 mm scan &amp; 1/1 mm reformats</b>					

**NOTES:**

- LMP on pts of child-bearing age
- Shield children when possible