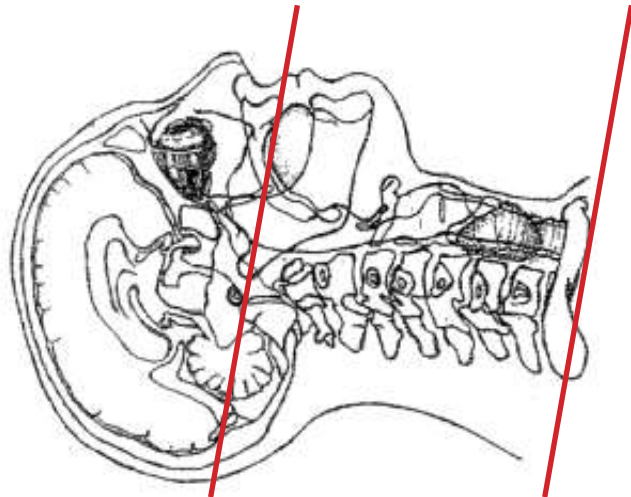
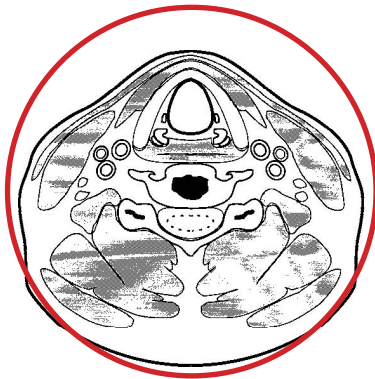

CT Neck with IV Contrast



Pt Position	Supine IOML perpendicular to table
Contrast	100 mL contrast
Injection Rate	2.5 mL/sec minimum 22g
Respiration	Breath - hold
Volume Acquisition Specs	Appropriate to achieve images as specified in the following tables Head FOV -mid-oral cavity to lung apices



Topogram - Scout					
PLANE	ALGORITHM	THICKNESS	INTERVAL	DFOV	
Axial +C	Soft Tissue	2.0 mm	2.0 mm	160-190 mm	
Coronal +C	Soft Tissue	2.0 mm	2.0 mm	160-190 mm	reformat
Sagittal +C	Soft Tissue	2.0 mm	2.0 mm	160-190 mm	reformat

NOTES:

- IOML perpendicular is optimal for potential reconstruction
- LMP on pts of child-bearing age
- Shield children when possible