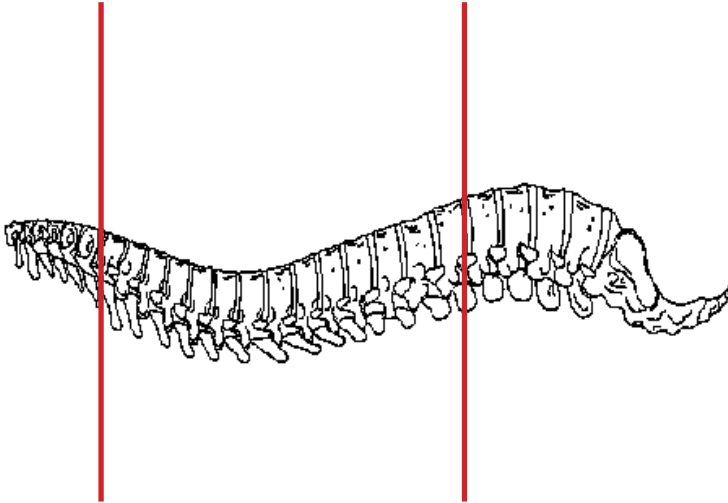
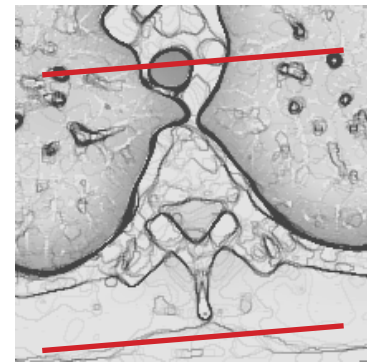
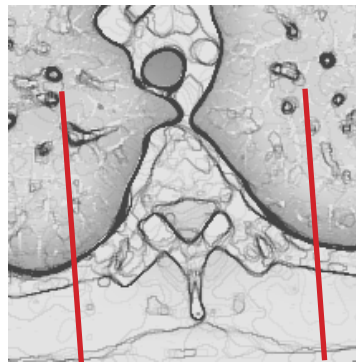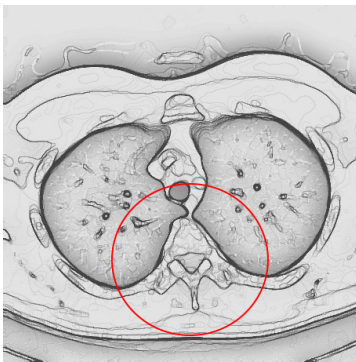


CT Thoracic Spine With IV Contrast POST MYELOGRAM



Pt Position	Supine
Contrast	Administered during myelogram
Injection Rate	N/A
Respiration	Breath - hold
Volume Aquisition Specs	Appropriate to achieve images as specified in the following tables Small FOV C7 to L1



PLANE	ALGORITHM	THICKNESS	DFOV	
Axial +C	Bone	2.5 mm	approx 180 mm	
Axial +C	Soft Tissue	2.5 mm	approx 180 mm	
Coronal +C	Bone	2.5 mm	approx 180 mm	reformat
Coronal +C	Soft Tissue	2.5 mm	approx 180 mm	reformat
Sagittal +C	Bone	2.5 mm	approx 180 mm	reformat
Sagittal +C	Soft Tissue	2.5 mm	approx 180 mm	reformat

NOTES:

- LMP on pts of child-bearing age
- Shield children when possible