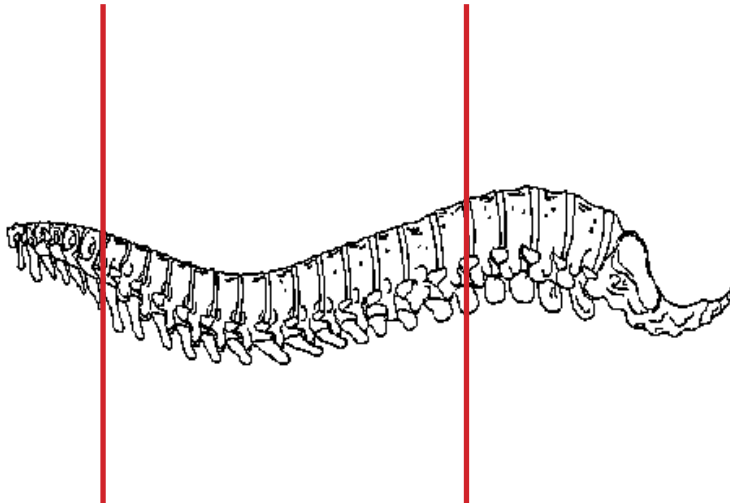
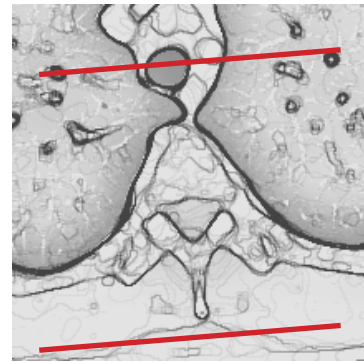
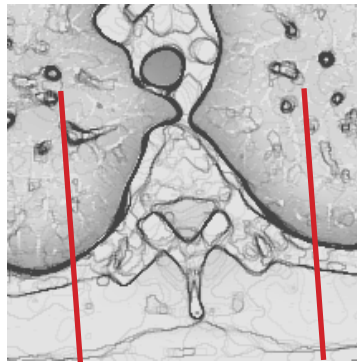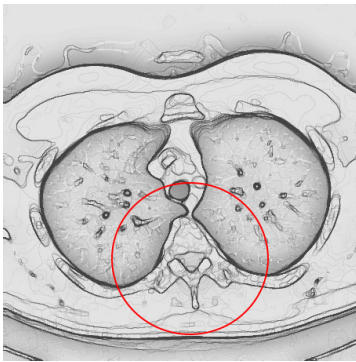


CT Thoracic Spine With IV Contrast



Pt Position	Supine
Contrast	100 mL
Injection Rate	1 mL/ssec, 90 sec delay
Respiration	Breath - hold
Volume Acquisition Specs	Appropriate to achieve images as specified in the following tables Small FOV C7 to L1

CT of the spine with contrast has limited applications, primarily for patients who are unable to have an MRI exam or for patients with prior hardware placement. All other indications should be discussed with radiologists and/or ordering physician as to why MRI exam would not be a more optimal exam for evaluation of malignancy, infection or disc disease



PLANE	ALGORITHM	THICKNESS	DFOV	
Axial	Bone	3.0 mm	approx 180 mm	
Axial	Soft Tissue	3.0 mm	approx 180 mm	
Coronal	Bone		approx 180 mm	reformat
Sagittal	Bone		approx 180 mm	reformat

NOTES:

- LMP on pts of child-bearing age
- Shield children when possible