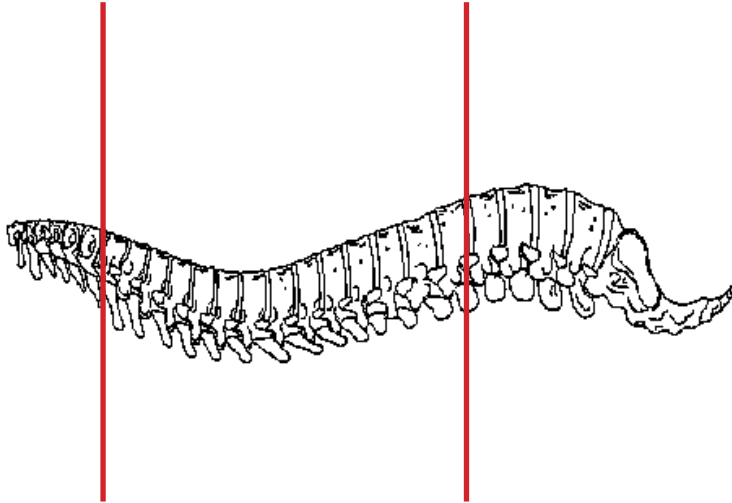
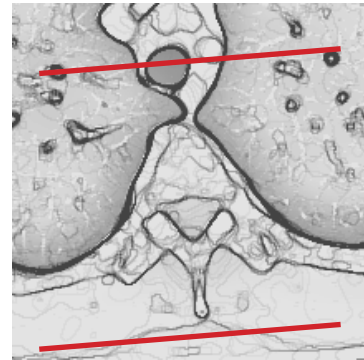
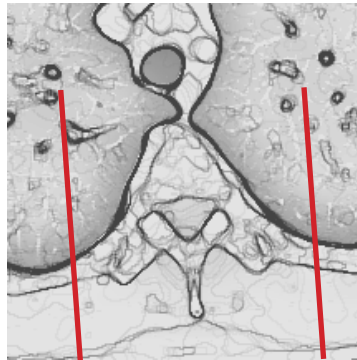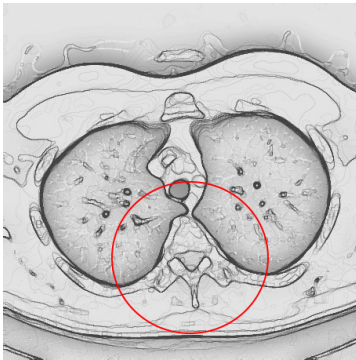


### CT Thoracic Spine Without IV Contrast



<b>Pt Position</b>	Supine
<b>Contrast</b>	None
<b>Injection Rate</b>	N/A
<b>Respiration</b>	Breath - hold
<b>Volume Aquisition Specs</b>	Appropriate to achieve images as specified in the following tables Small FOV C7 to L1
If CT C-T-L spine ordered, do as separate scans and use appropriate FOV for each area of spine	



PLANE	ALGORITHM	THICKNESS	DFOV	
Axial	Bone	3.0 mm	approx 180 mm	
Axial	Soft Tissue	3.0 mm	approx 180 mm	
Coronal	Bone		approx 180 mm	reformat
Sagittal	Bone		approx 180 mm	reformat

**NOTES:**

- LMP on pts of child-bearing age
- Shield children when possible