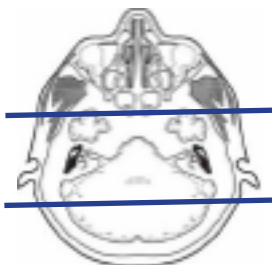


### MRI CRANIAL/FACIAL NERVE VII

**Indications** Bell's palsy, peripheral facial nerve palsy, hemifacial spasm, facial weakness, 7th nerve abnormality, facial paralysis, perineural spread cancer along facial nerve

**Localizer** scout

Plane	Sequence	Fat Sat	Mode	SLT / SP	FOV	Notes
Sagittal	T1			5/1.5	24 cm	
Axial	T1			5/1.5	24 cm	
Axial	T2			5/1.5	24 cm	
Axial	FLAIR	Y		5/1.5	24 cm	
Axial	DWI		ADC mapping	5/1.5	24 cm	B0 and B1000
Axial	GRE, SWI			5/1.5	24 cm	perform your scanner equivalent
3D Axial	T2		CiSS FIESTA	1.0	18 cm	perform your scanner equivalent
Coronal	T1			3/1	18 cm	parallel to brainstem include entire parotid
Axial	T1			3/1	18 cm	perpendicular to brainstem include entire parotid gland
Axial +C	T1	Y		3/1	18 cm	
Coronal +C	T1	Y		3/1	18 cm	parallel to brainstem include entire parotid
Axial +C	T1	Y		5/1.5	24 cm	through entire brain



Coronal thins +C

axial whole head

axial thins/3D

