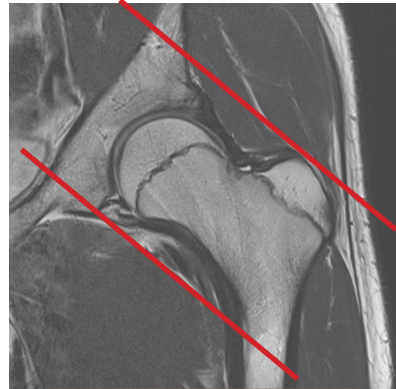
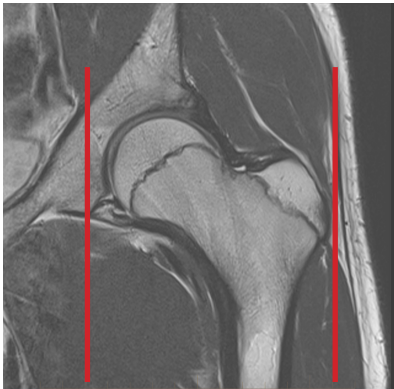
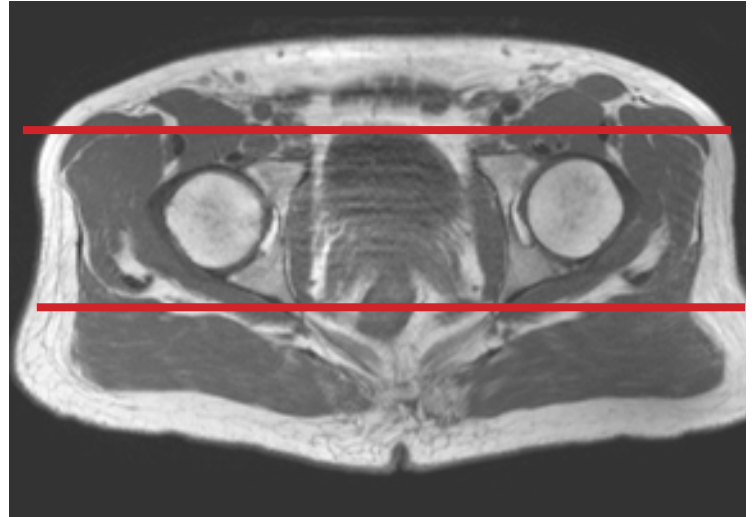
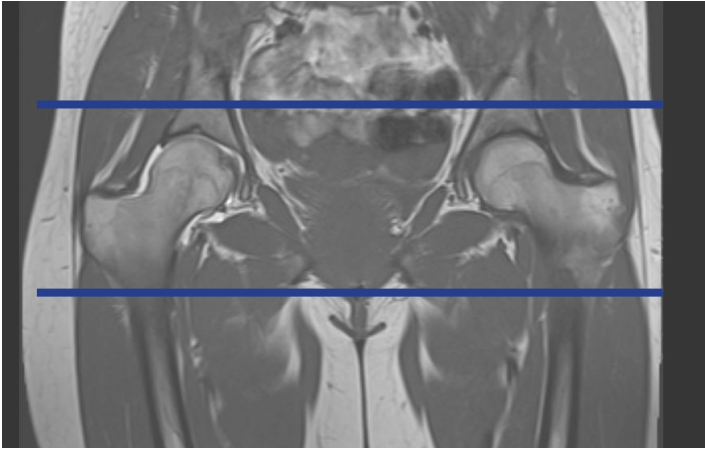


MRI HIP WITHOUT CONTRAST



Patient Position Supine - feet internally rotated and pt. made comfortable w/sponges

Localizer 3 - plane scout localizer

Plane	Sequence	Fat Sat	SLT / SP	FOV	Notes
Coronal	T1			Full FOV	entire pelvis
Coronal	STIR			Full FOV	entire pelvis
Coronal	PD	Y		small FOV	approx 1 slice anterior to and 1 slice posterior to acetabulum
Sagittal	PD	Y		small FOV	approx from outer cortex of the greater trochanter to the inner portion of the acetabulum
Axial obl	T2	Y		small FOV	approx 1 slice out of acetabulum superiorly to 1 slice out of acetabulum inferiorly