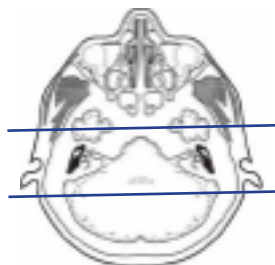


MRI IAC / CRANIAL NERVE VIII

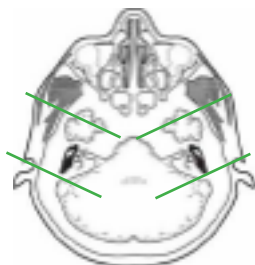
Indications Sensorineural hearing loss, 8th nerve abnormality, hearing loss, vertigo, tinnitus, ear and/or mastoid infection

Localizer scout

Plane	Sequence	Fat Sat	Mode	SLT / SP	FOV	Notes
Sagittal	T1			5/1.5	24 cm	
Axial	T1			5/1.5	24 cm	
Axial	T2			5/1.5	24 cm	
Axial	FLAIR	Y		5/1.5	24 cm	
Axial	DWI		ADC mapping	5/1.5	24 cm	B0 and B1000
Axial	GRE, SWI			5/1.5	24 cm	perform your scanner equivalent
3D Axial	T2		CiSS FIESTA		24 cm	perform your scanner equivalent
3D Parasagittal oblique	T2		CiSS FIESTA		18 cm	perform your scanner equivalent oblique/2 scans
Coronal	T1			2.5/0.2	18 cm	through IAC/temporal bones
Axial +C	T1	Y		2.5/0.2	18 cm	through IAC/temporal bones
Coronal +C	T1	Y		2.5/0.2	18 cm	through IAC/temporal bones
Axial +C	T1	Y		5/1.5	24 cm	through entire brain



Coronal thins +C



parasagittal oblique

