

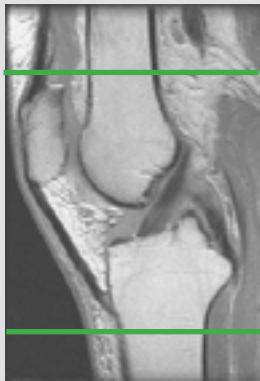
MRI KNEE ARTHROGRAM

Patient Position Supine - Knee extended fully (as much as pt. can tolerate). Minimize external/internal rotation

Localizer 3 - plane scout localizer

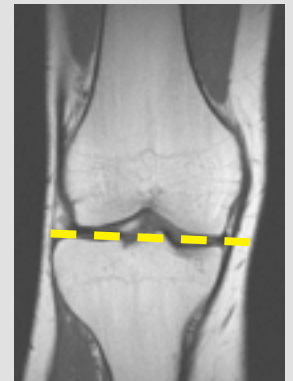
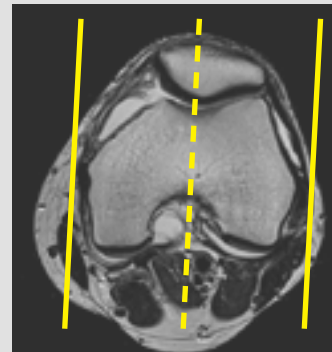
Plane	Sequence	Fat Sat	SLT / SP	FOV	Notes
Axial	T2	Y		14-16 cm	
Coronal +C	T1			16 cm	
Sagittal +C	T1	Y		16 cm	
Coronal +C	PD	Y		16 cm	
Sagittal +C	PD	Y		16 cm	

Image Plane Precriptions:



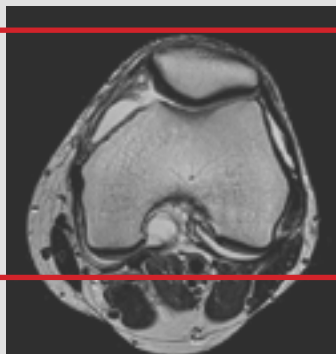
Axial imaging

- Cover from 2 Slices above the top of the Patella to the distal portion of the tibial tuberosity
- Perpendicular to the coronal and sagittal planes



Sagittal imaging

- Angle parallel to medial & lateral condyles
- Check positioning on coronal and angle parallel to tibial plateau
- Cover at least one slice past menisci on both sides



Coronal imaging

- Anterior patella through fibular head
- Angle parallel to posterior femoral condyles on axial scout