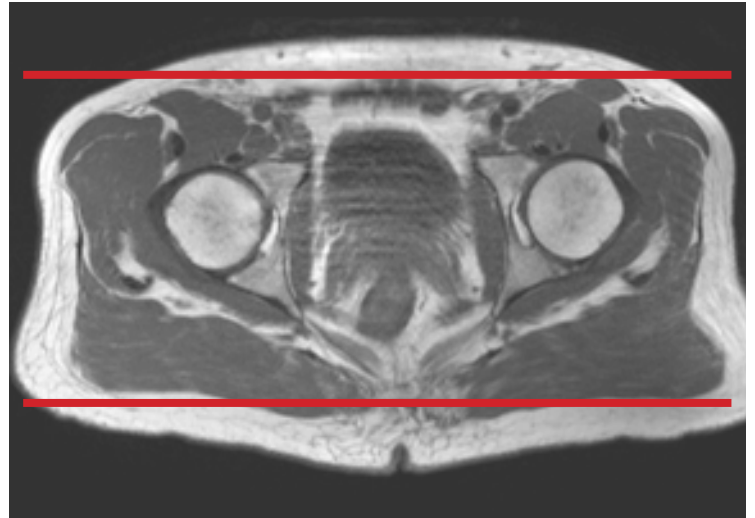
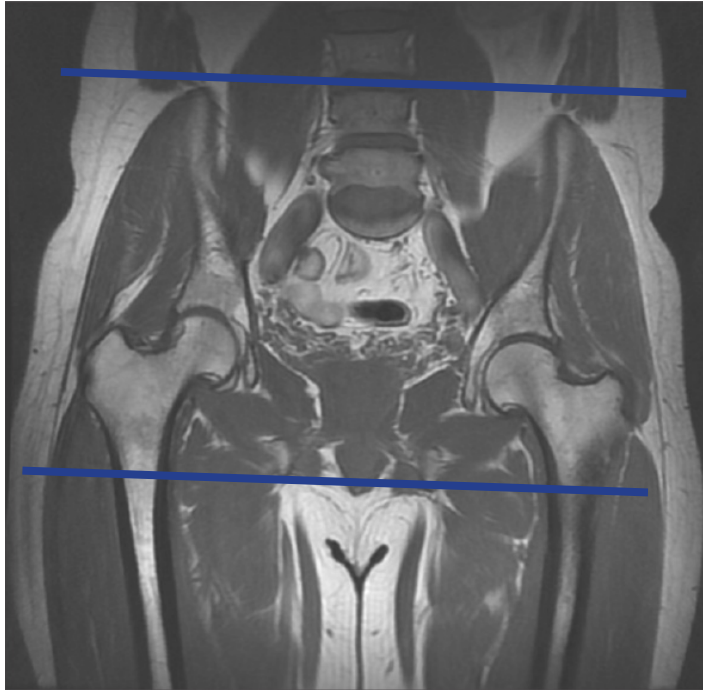


MRI PELVIS / BONY PELVIS



Patient Position Supine - feet internally rotated and pt. made comfortable w/sponges. Do not rotate if suspicion of femoral neck/hip fx

Localizer 3 - plane scout localizer

Plane	Sequence	Fat Sat	SLT / SP	FOV	Notes
Coronal	T1			Full FOV	anterior to ilium to just past sacrum
Coronal	STIR			Full FOV	anterior to ilium to just past sacrum
Axial	T1	N		Full FOV	just above iliac crest to level of lesser trochanter
Axial	T2	Y		Full FOV	just above iliac crest to level of lesser trochanter