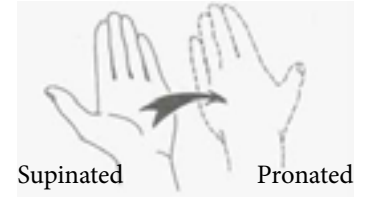


## MRI WRIST WITHOUT CONTRAST PROTOCOL



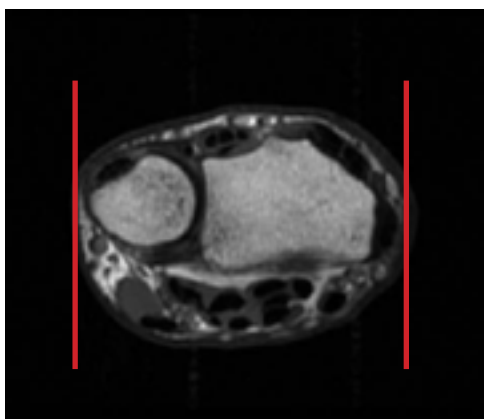
### WRIST WITHOUT CONTRAST

**Patient Position** Try to have wrist pronated and in superman position

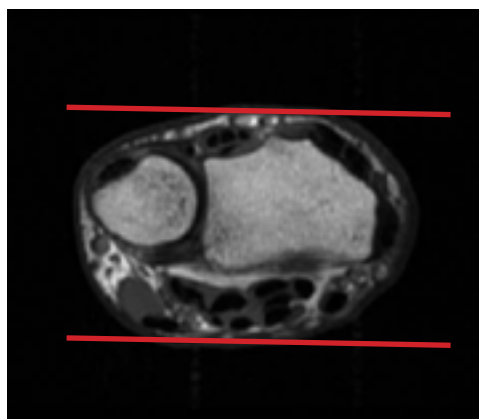
**Localizer** 3 - plane scout localizer

Plane	Sequence	Fat Sat	SLT / SP	**FOV	Notes
Axial	T2	Y	3 mm	8-10 cm	angle parallel to long axis of wrist from cor loc
Axial	T1		3 mm	8-10 cm	angle parallel to long axis of wrist from cor loc
Sagittal	T2	Y	3 mm	10 cm	perpendicular to axials
Coronal	T1		2 mm	10 cm	angle parallel to radius/lunate/capitate alignment
Coronal	T2	Y	2 mm	10 cm	angle parallel to radius/lunate/capitate alignment
3D Coronal	FE			10 cm	angle parallel to radius/lunate/capitate alignment

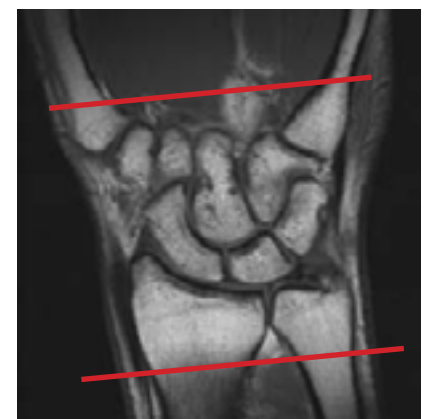\*\* FOV according to pt size



Sagittal Plane



Coronal Plane



Axial Plane