

**MR**

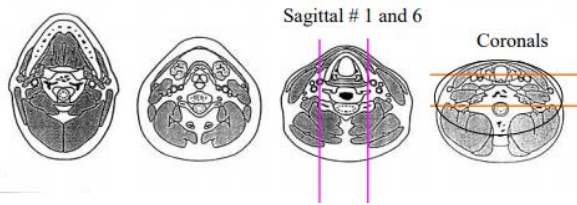
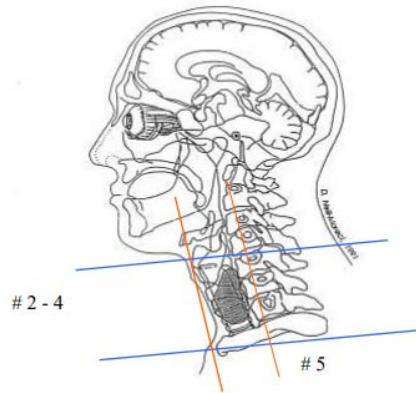
**NECK**

ACQUISITION	1	2	3	4	5	6	7	8	9
PLANE	Sag	Axial	Axial	Axial	Axial	Sag	Axial	Cor Angled	Sag
SEQUENCE	T1	T1	T2	T2 FS	DWI	T2	T1	T1	T1FS
CONTRAST							Post Gad	Post Gad	Post Gad
SLT/SP	3.0 /0. 0	3.0/ 0.0	3.0/ 0.0	3.0/ 0.0	3.0/ 0.0	3.0/ 0.0	3.0/ 0.0	3.0/0.0	3.0/0 .0
FOV	24 cm	24 cm	24 cm	24 cm	24 cm	24 cm	24 cm	24 cm	24 cm

**THYROID/CERVICAL TRACHEA AND CERVICAL ESOPHAGUS WITHOUT AND WITH**

**Special Instructions:**

Use Neck Coil w anterior element. Spine coils are suboptimal. Neurovascular Coil is good.



Any deviation from protocol MUST be radiologist approved. Rad Director will be notified if this occurs without prior approval.

4/29/2020