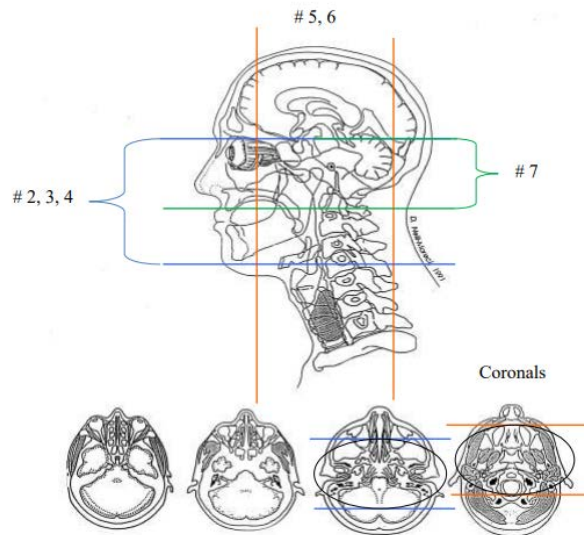


ACQUISITION	1	2	3	4	5	6	7	8	9	10	11
PLANE	Axial	Sag	Axial	Axial	Axial	Axial	Axial	Cor	Axial	Cor	Axial
SEQUENCE	DWI	T1	T2	T2 Flair	Fiesta or B-FFE	T2 FS	T1	T1	T1FS	T1FS	T1
CONTRAST									Yes	Yes	Yes
SLT/SP	5.0/1.5	5.0/1.5	5.0/1.5	5.0/1.5	1.0	3.0/1.0	3.0/1.0	3.0/1.0	3.0/1.0	3.0/1.0	5.0/1.5
FOV	24.0	24.0	24.0	24.0	18.0	18.0	18.0	18.0	18.0	18.0	24.0

Special Instructions:

Axial Whole Brain images Angled to AC-PC line
 Small FOV axial images are angled parallel to the brainstem
 Small FOV coronal images are angled perpendicular to the brainstem
 FIESTA or B-FFE images are angled Perpendicular to the brainstem
AXIAL GRE, 2D/3D SWAN(GE) or ven BOLD images Optional

MR TRIGEMINAL CRANIAL NERVE V



Any deviation from protocol MUST be radiologist approved. Rad Director will be notified if this occurs without prior approval.

4/27/2020

