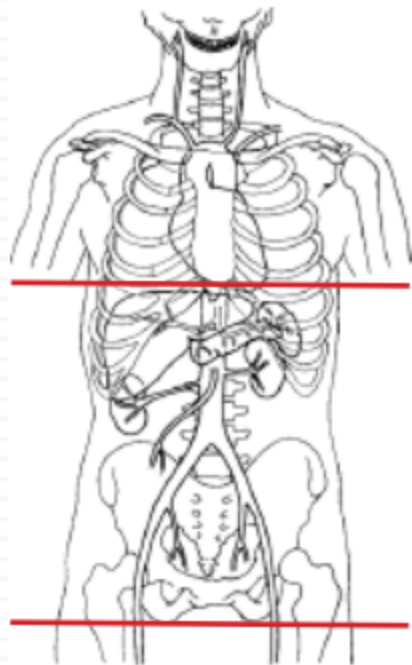


## CT Abdomen/Pelvis without contrast - STONE PROTOCOL



<b>Indications</b>	<b>flank pain, hematuria</b>
Patient Position	Supine
Respiration	Breath- hold
Scan Parameters	dome of diaphragm through ischial tuberosity

<b>PLANE</b>	<b>ALGORITHM</b>	<b>THICKNESS</b>	<b>DFOV</b>	<b>RECONS</b>
Axial	Abdomen	5.0 mm	pt largest + 4 cm	
Coronal	Abdomen	5.0 mm		X
Sagittal	Abdomen	5.0 mm		X

**NOTES:**

- LMP on pts of child-bearing age
- Shield children when possible