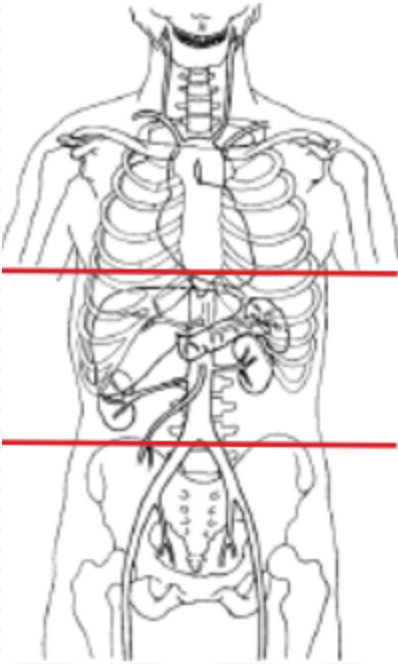


CT ADRENAL PROTOCOL



Indications	mass found on previous imaging
Patient Position	Supine
Contrast	IV = 100 mL
Injection rate	2.5 mL/sec minimum 22 g prefer 18 g
Respiration	Breath- hold
Scan Parameters	dome of diaphragm to iliac crest only for all phases

PLANE	ALGORITHM	THICKNESS	DFOV	RECONS
Axial	Abdomen	3.0 mm	pt largest + 4 cm	Non-contrast only if no recent non-contrast scan
Axial + C	Abdomen	3.0 mm		Portovenous phase
Axial + C	Abdomen	3.0 mm		15 minute delay from initial scan
Coronal + C	Abdomen	3.0 mm		MPR reformat -portovenous only
Sagittal + C	Abdomen	3.0 mm		MPR reformat- portovenous only

NOTES:

- Use at least 22g needle
- Follow GFR and Metformin protocols for contrast studies
- LMP on pts of child-bearing age
- Shield children when possible