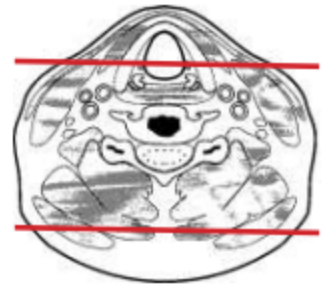
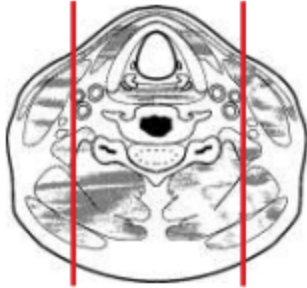
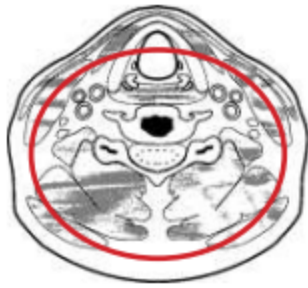
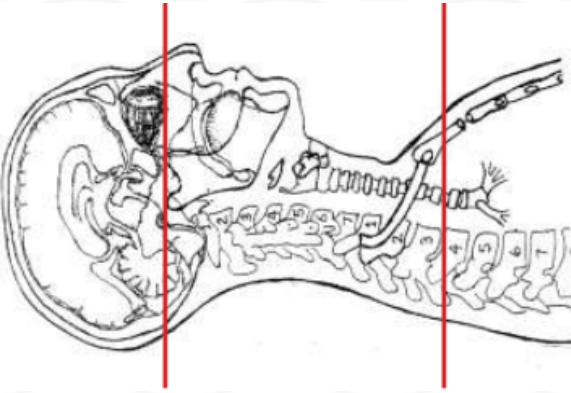CT CERVICAL SPINE WITHOUT IV CONTRAST

| | |
|------------------|---|
| Indications | Trauma. **IF CT C- T- L spine ordered, do as separate scans and use appropriate FOV for each area of the spine. |
| Patient position | Supine, IOML perpendicular to table |
| Contrast | NONE |
| Injection rate | NONE |
| Respiration | Breath hold |
| Scan parameters | Sella turcica to T3. Use small SFOV |



| PLANE | ALGORITHM | THICKNESS | DFOV | |
|--------------------|-------------|-----------|---------------|-----------|
| Axial | Bone | 3.0 mm | approx 140 mm | |
| Axial | Soft tissue | 3.0 mm | | |
| Coronal & Sagittal | Bone | 3.0 mm | | Reformats |

NOTES:

- LMP on pts of child-bearing age
- Shield children when possible
- Follow GFR and metformin protocol for contrast studies

Any deviation from protocol MUST be Radiologist approved. Rad Director will be notified if this occurs without prior approval.