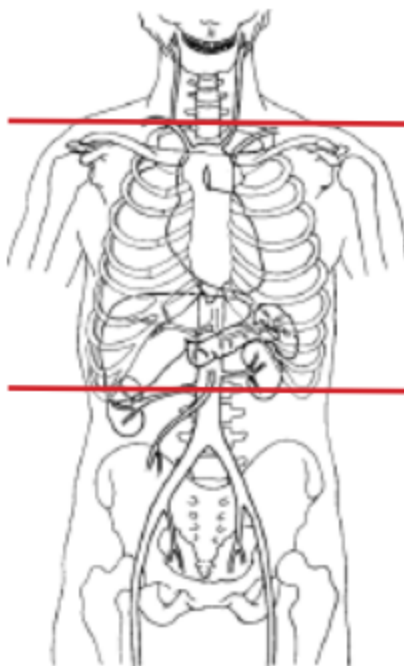


CT CHEST HI RES (NON CONTRAST)



Indications	Interstitial lung disease, pulmonary fibrosis
Patient Position	Supine & Prone
Contrast	NONE
Respiration	Breath- hold
Scan Parameters	just above lung apices through adrenals

PLANE	ALGORITHM	THICKNESS	INTERVAL	DFOV	REFORMATS
Axial - SUPINE	Mediastinum	5.0 mm		pt largest + 4 cm	
Axial	Lung	5.0 mm			X
Sagittal	Mediastinum	5.0 mm			X
Coronal	Mediastinum	5.0 mm			X
Axial	MIP	8.0 mm	3.0 mm		X
Axial	Lung/ very sharp kernel	1.0 mm			1 mm for 2 consecutive cuts every 10 mm
Axial - PRONE	Lung/ very sharp kernel	1.0 mm			1 mm for 2 consecutive cuts every 10 mm

NOTES:

- LMP on patients of child-bearing age
- Shield children when possible