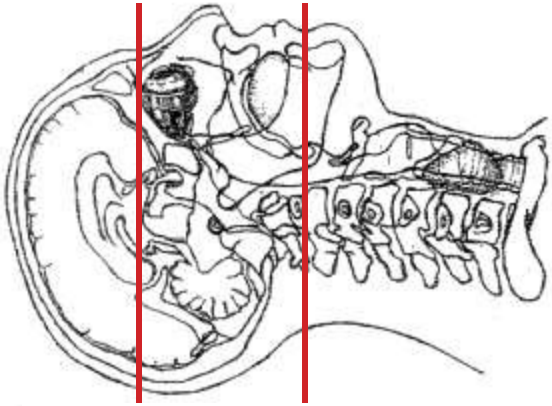
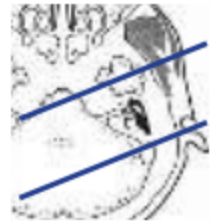
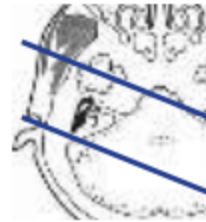
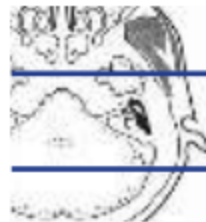
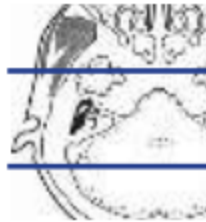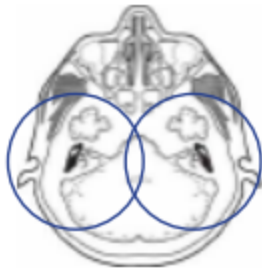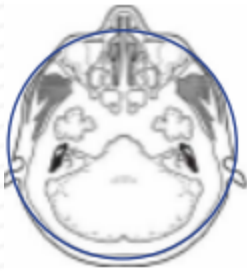CT IAC / TEMPORAL BONE PROTOCOL



Patient position	Supine, IOML perpendicular to table
Contrast	NONE
Injection rate	NONE
Respiration	Breath hold
Scan parameters	Appropriate to achieve images as specified in the following table. Above sella through hard palate. HEAD SFOV



PLANE	ALGORITHM	THICKNESS	DFOV	
Axial	Soft tissue	2.0 mm	approx 180 mm	above sella through hard palate
Right Axial	Bone	1.0 mm	approx 90 mm	above sella through hard palate
Left Axial	Bone	1.0 mm	approx 90 mm	above sella through hard palate
Coronal (Right and left)	Bone	1.0 mm	approx 90 mm	MPR reformat TMJ through IAC
Sagittal (Right and left)	Bone	1.0 mm	approx 90 mm	MPR reformat Anterior to TMJ through IAC parallel to IAC

NOTES:

- LMP on pts of child-bearing age
- Shield children when possible
- Follow GFR and metformin protocol for contrast studies

Any deviation from protocol MUST be Radiologist approved. Rad Director will be notified if this occurs without prior approval.