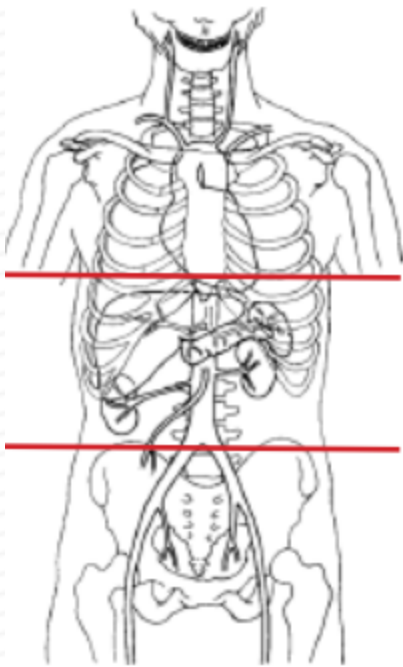
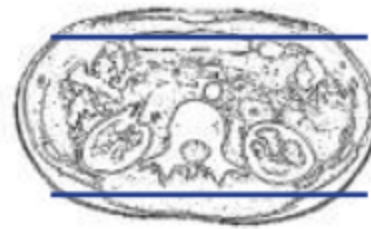
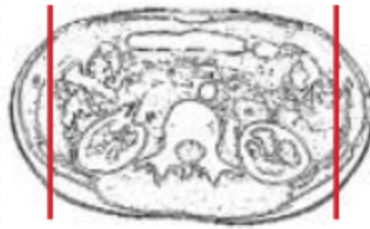
CT LIVER MASS PROTOCOL



Indications	mass found on previous imaging
Patient Position	Supine
Contrast	IV = 100 mL
Injection rate	2.5 mL/sec minimum 22 g prefer 18 g
Respiration	Breath- hold
Scan Parameters	dome of diaphragm to iliac crest only for all phases
Special note	NON-contrast CT abd NOT needed for liver masses



PLANE	ALGORITHM	THICKNESS	DFOV	RECONS/ Reformats
Axial + C	Abdomen	3.0 mm	pt largest + 4 cm	ARTERIAL - use bolus tracking
Axial + C	Abdomen	3.0 mm		VENOUS
Axial + C	Abdomen	3.0 mm		5 minute DELAY
Coronal + C	Abdomen	3.0 mm		MPR reformats- use venous phase
Sagittal + C	Abdomen	3.0 mm		MPR reformats- use venous phase

NOTES:

- Use at least 22g needle
- Follow GFR and Metformin protocols for contrast studies
- LMP on pts of child-bearing age
- Shield children when possible