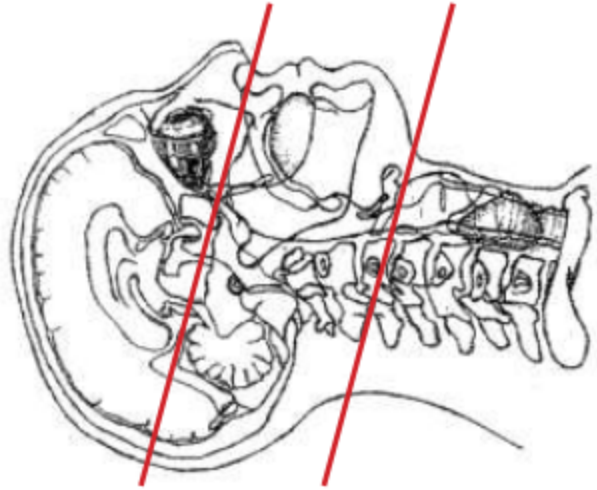


CT PAROTID / SUBMANDIBULAR GLAND WITH IV CONTRAST



Indications	Soft tissue mass (place marker on ROI), neck swelling.
Patient position	Supine, IOML perpendicular to table
Contrast	IV = 100 mL
Injection rate	2.5 mL/sec minimum 22 g
Respiration	Breath hold - NO SWALLOWING
Scan parameters	Suborbital cavity to hyoid bone. Use head FOV

PLANE	ALGORITHM	THICKNESS	DFOV	
Axial + C	Soft tissue	1.5 mm	approx 160 - 180 mm	
Coronal & Sagittal + C	Bone	2.0 mm x 2.0 mm		Reformats

NOTES:

- LMP on pts of child-bearing age
- Shield children when possible
- Follow GFR and metformin protocol for contrast studies

Any deviation from protocol MUST be Radiologist approved. Rad Director will be notified if this occurs without prior approval.