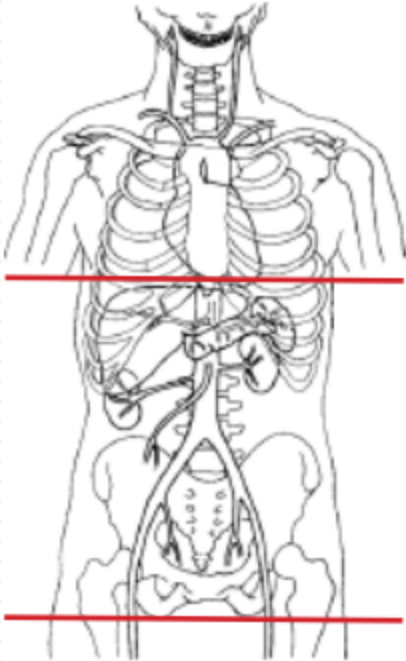


CT UROGRAM / HEMATURIA PROTOCOL



Indications	flank pain, hematuria
Patient Position	Supine
Contrast	IV = 100 mL
Injection rate	2.5 mL/sec minimum 22 g prefer 20 g
Respiration	Breath- hold
Scan Parameters	dome of diaphragm to ischial tuberosity
Special note	Patient should drink 1 liter of water 30 minutes prior to scan.

PLANE	ALGORITHM	THICKNESS	DFOV	
Axial	Abdomen	5.0 mm	pt largest + 4 cm	Non contrast
Axial + C	Abdomen	5.0 mm		90 sec delay
Axial + C	Abdomen	5.0 mm		10 minute DELAY. Techs call rad to see if distal ureters opacified. If not, lay patient prone & rescan in 15 minutes.
Coronal + C	Abdomen	3.0 mm		MPR reformats on 90 sec delay AND 10 min delay
Sagittal + C	Abdomen	3.0 mm		MPR reformats on 90 sec delay AND 10 min delay

NOTES:

- Use at least 22g needle
- Follow GFR and Metformin protocols for contrast studies
- LMP on pts of child-bearing age
- Shield children when possible

Any deviation from protocol MUST be Radiologist approved. Rad Director will be notified if this occurs without prior approval.