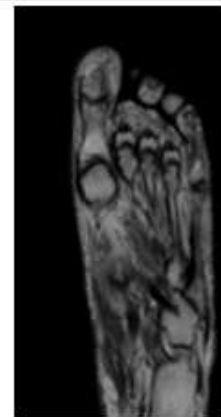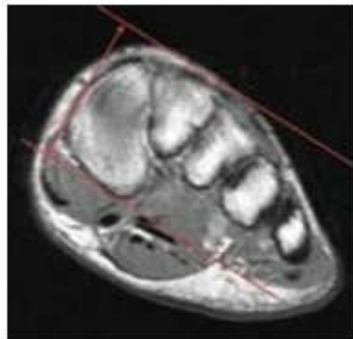
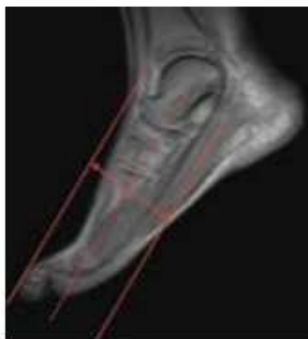


## MRI FOOT (WHOLE) WITHOUT CONTRAST

<b>Indications</b>	<b>General pain, mid-foot pain</b>
Scan Range	Variable according to area of interest/ body part.
FOV	Fits to patient/ body part.
Position	Supine. Place in foot coil so metatarsals near center.
Localizer	3 plane scout localizer
NOTES	<b>REMOVE SOCKS or STOCKINGS if any</b>
	Increase FOV if needed for patient size / pathology

PLANE	SEQUENCE	FAT SAT	MODE	SLT/SP	FOV	NOTES
Sagittal	T1				small FOV	
Axial	T1				small FOV	
Coronal	T2	Y			small FOV	
Sagittal	STIR				small FOV	
Axial	PD	Y			small FOV	

### POSITIONING AND PLANES



Prescribe AXIALS off sagittal and coronal scout

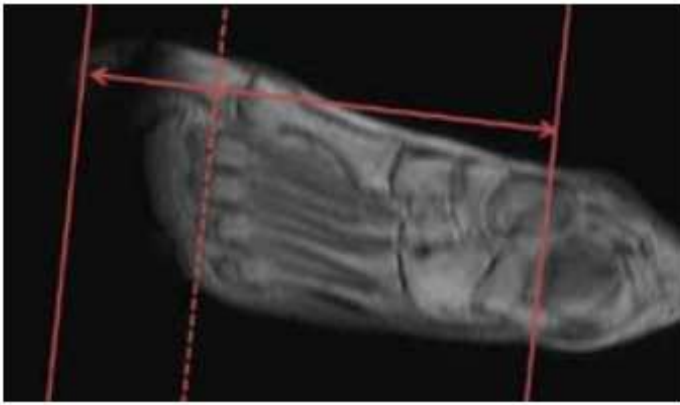
Example resulting image

#### AXIALS - LONG AXIS

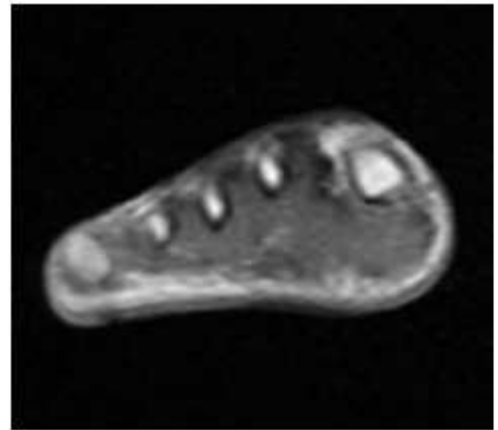
- Use Sag LOC and angle parallel to the shaft of either the 2nd or 3rd metatarsals and at least cover the soft issues superior and inferior to the MTP joints
- Cover all of the toes and as far proximal as the field of view allows. THIS SHOULD BE TO THE TARSAL BONES
- Angle parallel to the TOP LINE of the 2nd and 3rd metatarsal necks

Any deviation from protocol MUST be Radiologist approved. Rad Director will be notified if this occurs without prior approval.

## POSITIONING AND PLANES



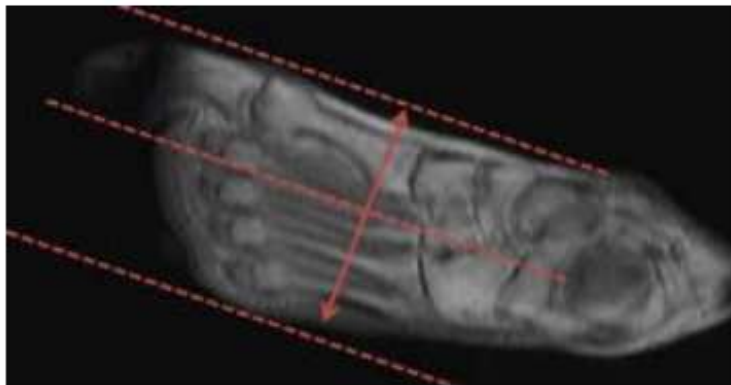
Prescribe CORONAL off axial plane



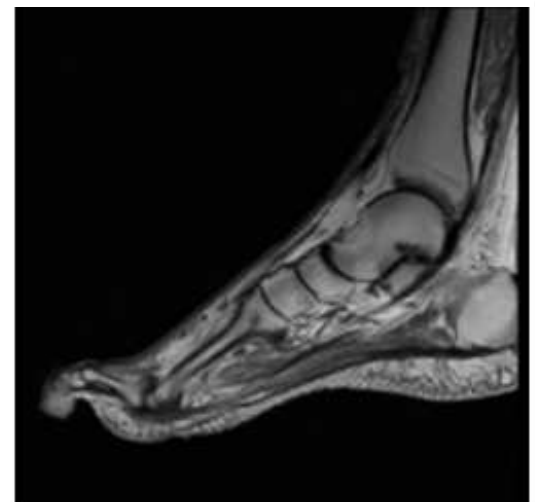
Example resulting image

### CORONAL - SHORT AXIS

- Perpendicular to Axial - long axis
- Angled parallel to 2nd MTP joint or perpendicular to 2nd metatarsal shaft
- Cover at least to the talonavicular joint



Prescribe SAGITTAL off axial plane



Example resulting image

### SAGITTAL

- Perpendicular to AXIAL and CORONAL
- Parallel to 2nd metatarsal shaft on Axial sequence
- Cover from tips of the toes (if requested) as far proximal as the FOV allows
- Cover from medial margin of 1st MTP joint as far lateral as the slices go (to cover all of the MTP joints)