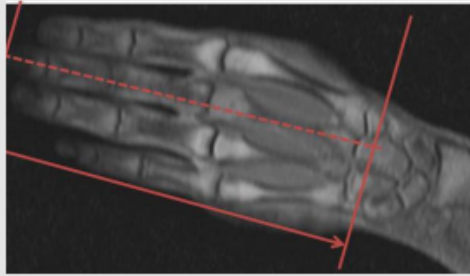


MRI HAND WITHOUT CONTRAST

Scan Range	Variable according to area of interest/ body part.
FOV	Fits to patient/ body part.
Position	PRONE and patient in Superman position if possible
Localizer	3 plane scout localizer


PLANE	SEQUENCE	FAT SAT	FOV	NOTES
Axial	T1		12 - 16 cm	angle parallel to long axis of wrist from cor loc
Axial	T2		12 - 16 cm	angle parallel to long axis of wrist from cor loc
Axial	STIR		12 - 16 cm	perpendicular to axials
Sagittal	PD	Y	12 - 16 cm	angle parallel to radius/lunate/capitate alignment
Coronal	T1		12 - 16 cm	angle parallel to radius/lunate/capitate alignment
Coronal	PD	Y	12 - 16 cm	angle parallel to radius/lunate/capitate alignment

Image Plane Precriptions:



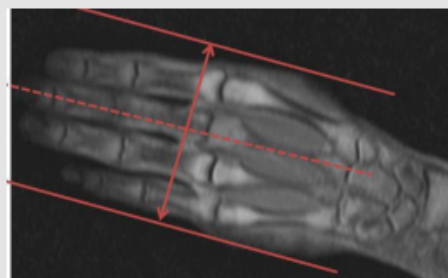
Axial imaging

- Use COR LOC and angle perpendicular to 3rd Digit
- Cover from tip of finger to CMC joints



Coronal imaging

- Use Axial LOC and angle parallel to the 2nd-5th MCP joints, and try to cover through the majority of the thumb
- Use Sagittal LOC and angle parallel to 3rd digit and 3rd metacarpal



Sagittal imaging

- Perpendicular to Coronal and Axial Sequences
- Cover through all of the digits if the patient has non-localizable pain or if they are looking for a generalized arthritis (USE THICKER SLICES)
- If a digit is symptomatic, then cover through that digit and an adjacent digit (USE THINNER SLICES)