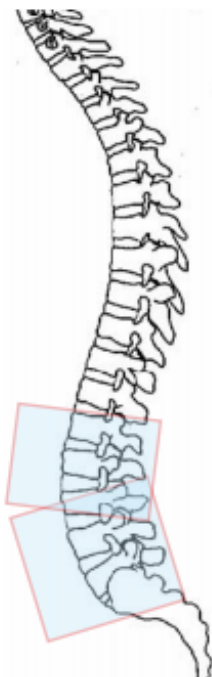


MRI L-SPINE WITHOUT CONTRAST

Indications	Radiculopathy, degenerative disease, disc disease, fracture, osteoporosis
Localizer	3 plane scout
Note	Any patient that had prior lumbar surgery MUST be scanned without and with contrast. Contact the Radiologist if ordered without prior to scanning the patient.
	Contact the Radiologist if the patient has multi-level spine studies ordered before performing any of the studies.

PLANE	SEQUENCE	FAT SAT	SLT/SP	FOV	NOTES
Sagittal	T2		4 / 1	28 cm	Cover from T12 through S2
Sagittal	T1		4 / 1	28 cm	Cover from T12 through S2
Sagittal	STIR		4 / 1	28 cm	Cover from T12 through S2
Axial	T1		4 / 1	16 - 18 cm	Scan axials as 2 continuous blocks through L spine. 1. T12-L2/3, angle to L2. 2. L3-S1, angle to L4/5.
Axial	T2		4 / 1	16 - 18 cm	These may need to be scanned separately if you experience cross-talk/artifact. Do not prescribe axials in one single block without prior radiologist approval.



- Abnormalities should be in one stack of axials.
- Do not place the end or beginning of the stack within the abnormality!

