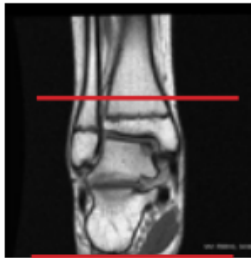
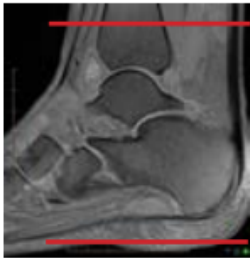

MRI ANKLE WITHOUT CONTRAST

Scan Range	Variable according to area of interest/ body part.
FOV	Fits to patient/ body part.
Position	Supine. Place in foot coil so metatarsals near center.
Localizer	3 plane scout localizer
NOTES	REMOVE SOCKS or STOCKINGS if any

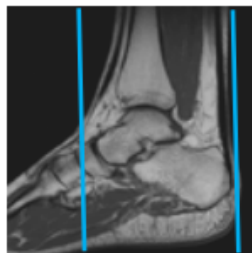
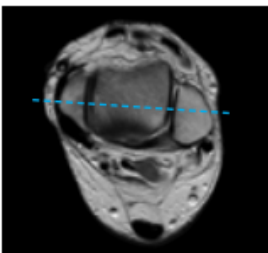
PLANE	SEQUENCE	FAT SAT	MODE	SLT/SP	FOV	NOTES
Axial	T1				14 - 16 cm	
Axial	T2	Y			16 cm	
Sagittal	STIR				16 cm	
Sagittal	T1				16 cm	
Coronal	PD	Y			16 cm	

POSITIONING AND PLANES



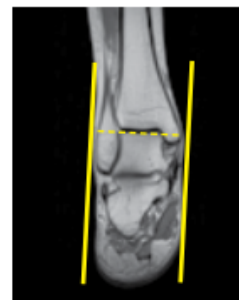Axial imaging

- Perpendicular to COR and SAG
- Cover from 3-4 Slices above the inferior margin of the tibiotalar joint down as far as the slices go



Coronal imaging

- Use axial LOC and angle perpendicular to the inner cortex of the medial malleolus
- Use sagittal LOC and angle parallel to distal tibial shaft and cover from the talonavicular joint to at least 2 slices posterior to the talus



Sagittal imaging

- Perpendicular to COR
- Angled perpendicular to talar dome
- Cover at least 1 slice out of both malleoli
- All of the plantar soft tissues should be included in the FOV

Any deviation from protocol MUST be Radiologist approved. Rad Director will be notified if this occurs without prior approval.