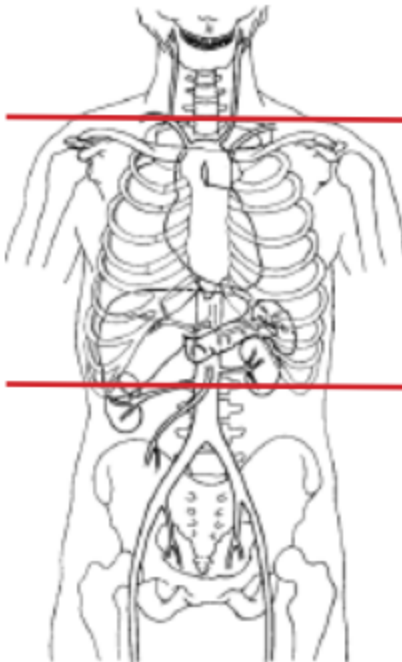


CT CHEST / ESOPHAGRAM (Emergency only)



| | |
|--------------------|---|
| Indications | The is an emergency after hours esophagram for esophageal perforation and/or impacted foreign body. |
| Patient Position | Supine |
| Contrast | NO IV. Esophagram/Barium swallow - low osmolar oral contrast (Omnipaque or Isovue) diluted with water at 1:1 ratio. |
| Injection rate | NONE |
| Respiration | Breath- hold |
| Scan Parameters | just above lung apices through adrenals |
| NOTES | NEEDS prior approval from Radiologist. Notify Rad when it is completed. |

1. Low Osmolar oral contrast (Omnipaque or Isovue diluted with water 1:1 ratio) should be given right before the scan. One cup of low osmolar contrast should be administered orally while the patient is being scanned if at all possible. Patient should drink $\frac{3}{4}$ the cup and sip the other $\frac{1}{4}$ through the straw while being imaged.

2. An ER nurse or MD MUST be present at the time of ingestion of the contrast in the event the patient aspirates the contrast.

3. **DO NOT USE BARIUM.** Please DO a Pre-Contrast CT study prior to giving the oral.

| PLANE | ALGORITHM | THICKNESS | DFOV | REFORMATS |
|-----------------------|-----------|-----------|-------------------|-----------|
| Axial | Abdomen | 5.0 mm | pt largest + 4 cm | |
| Axial + oral contrast | Abdomen | 5.0 mm | | |
| Axial | Lung | 5.0 mm | | X |
| Sagittal | Abdomen | 5.0 mm | | X |
| Coronal | Abdomen | 5.0 mm | | X |