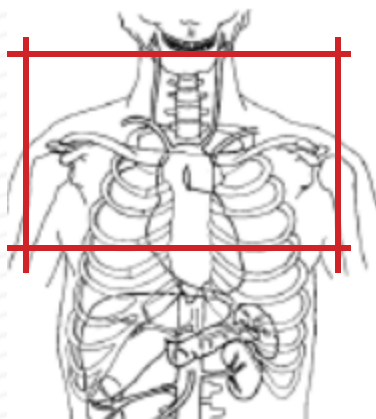


# MRI CHEST WITHOUT & WITH CONTRAST : Thoracic Outlet



Indications	Thoracic outlet syndrome
Patient Position	Supine, arms adducted out of FOV
Contrast	Without and with
Respiration	Breath- hold should be encouraged
Scan Parameters	Center at aortic arch, body coil
Special notes	If unsure of scan parameters, check with Radiologist.
	<b>PLACE IV in CONTRALATERAL extremity to symptoms</b>

PLANE		Fat Sat	Mode	SLT/SP	FOV	NOTES
Coronal: HIGH RES	T1 WTSE				fit to patient	
Axial: HIGH RES	T1 WTSE				fit to patient	
Sagittal: HIGH RES	T1 WTSE				fit to patient	
Axial 3D	3D GRE				fit to patient	BREATH HOLD
Coronal 3D	3D MRA				fit to patient	BREATH HOLD
Test bolus: Timed off aortic arch						
Coronal + C	3D MRA				#1: at test bolus	BREATH HOLD
Coronal + C	3D MRA				#2: 12 sec delay	BREATH HOLD
Coronal + C	3D MRA				#3: 40 sec delay	BREATH HOLD
Axial + C	3D MRA					BREATH HOLD
CHANGE PT Position: Arms ABDUCTED external rotation						Repeat Variable scout
Coronal + C	3D MRA		2 acquisitions			BREATH HOLD
Coronal + C	3D MRA		isotropic voxel, reduce voxel size			BREATH HOLD
Axial + C	3D MRA - GRE		volume interpolated GRE			BREATH HOLD
Sagittal + C HIGH RES	T1 WTSE					for assessment of brachial plexus compression

Any deviation from protocol MUST be Radiologist approved. Rad Director will be notified if this occurs without prior approval.