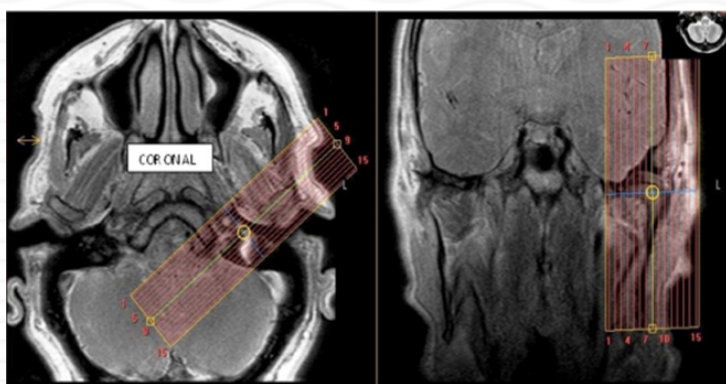


MRI TMJ Without & with contrast

Indications	inflammatory arthritis, etc
Notes	Always scan bilaterally. Scan right and left sides separately. LABEL sides correctly.

PLANE	SEQUENCE	FAT SAT	MODE	SLT/SP	FOV	NOTES
Axial	T1			4/1	23 cm	Angle to Corpus - skill base to vertex
Axial	T1	Y		4/1		Angle to Corpus - skill base to vertex
Sagittal (right & left)	PD closed		TSE	2/0	12 cm	Perpendicular to long axis
Sagittal (right & left)	T2 closed		TSE	2/0	12 cm	Perpendicular to long axis
Coronal (right & left)	T2 closed		TSE	2/0	12 cm	Parallel to long axis
Sagittal (right & left)	PD open		TSE	2/0	12 cm	Perpendicular to long axis
Axial + C	T1	Y		4 /1	23 cm	

Coronal



Sagittal

