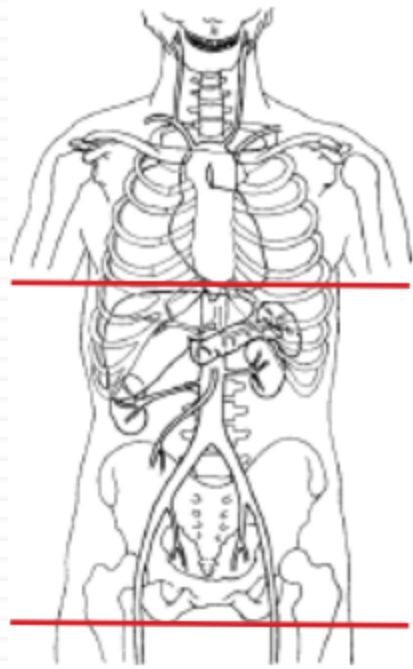


CT Abdomen/Pelvis without contrast - STONE PROTOCOL



Indications	flank pain, hematuria
Patient Position	Supine
Respiration	Breath- hold
Scan Parameters	dome of diaphragm through ischial tuberosity

PLANE	ALGORITHM	THICKNESS	DFOV	RECONS
Axial	Abdomen	5.0 mm	pt largest + 4 cm	
Coronal	Abdomen	5.0 mm		X
Sagittal	Abdomen	5.0 mm		X

NOTES:

- LMP on pts of child-bearing age
- Shield children when possible