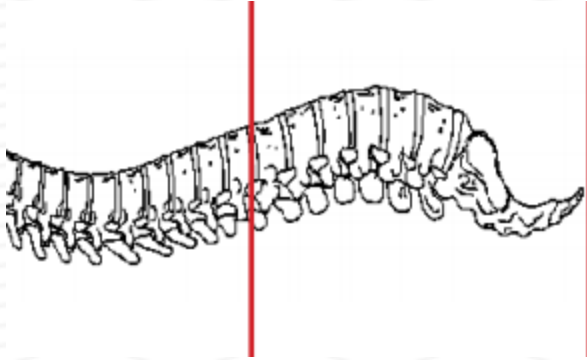
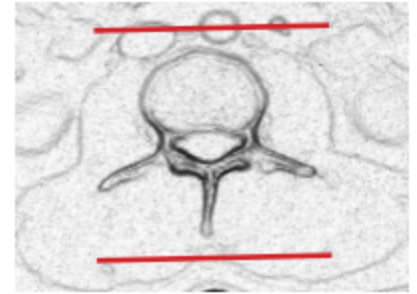
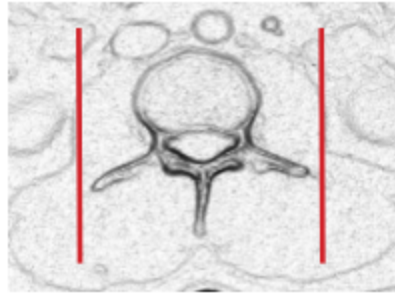
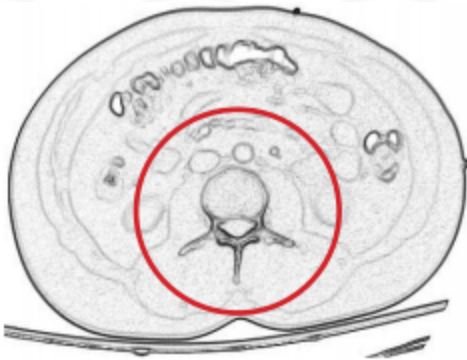


CT LUMBAR SPINE WITH CONTRAST - POST MYELOGRAM



Patient position	Supine
Contrast	ADMINISTERED DURING MYELOGRAM
Injection rate	NONE
Respiration	Quiet breathing
Scan parameters	T 11 / 12 through coccyx. Use small SFOV



PLANE	ALGORITHM	THICKNESS	DFOV	
Axial + C	Bone	2.5 mm	approx 180 mm	
Axial + C	Soft tissue	2.5 mm		
Coronal & Sagittal + C	Bone	2.5 mm		Reformats
Coronal & Sagittal + C	Soft tissue	2.5 mm		Reformats
	NOTE	2.5 mm thickness preferred	minimum 3 mm slice thickness	

NOTES:

- LMP on pts of child-bearing age
- Shield children when possible
- Follow GFR and metformin protocol for contrast studies

Any deviation from protocol MUST be Radiologist approved. Rad Director will be notified if this occurs without prior approval.