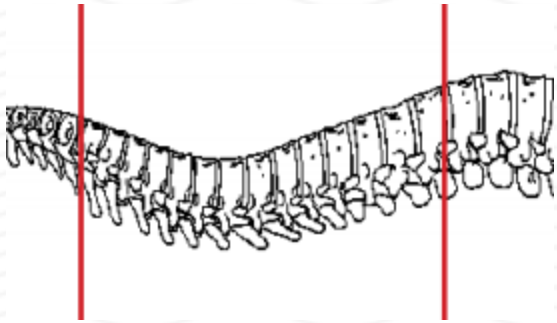
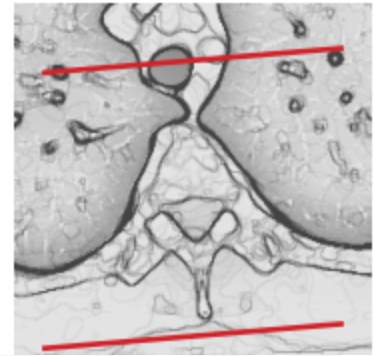
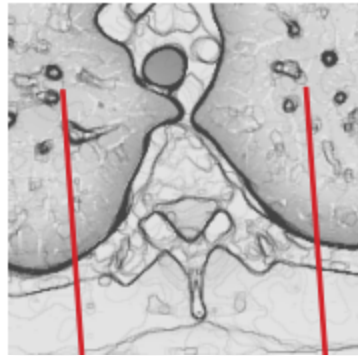
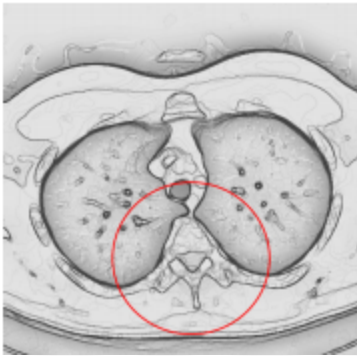


CT THORACIC SPINE WITH CONTRAST - POST MYELOGRAM



Patient position	Supine
Contrast	ADMINISTERED DURING MYELOGRAM
Injection rate	NONE
Respiration	Hold breath
Scan parameters	C7 through L1. Use small SFOV



PLANE	ALGORITHM	THICKNESS	DFOV	
Axial + C	Bone	2.5 mm	approx 180 mm	
Axial + C	Soft tissue	2.5 mm		
Coronal & Sagittal + C	Bone	2.5 mm		Reformats
Coronal & Sagittal + C	Soft tissue	2.5 mm		Reformats

NOTES:

- LMP on pts of child-bearing age
- Shield children when possible
- Follow GFR and metformin protocol for contrast studies

Any deviation from protocol MUST be Radiologist approved. Rad Director will be notified if this occurs without prior approval.