

## MRA NECK WITHOUT & WITH CONTRAST

<b>Indications</b>	<b>Intracranial arterial stenosis, occlusion, abnormality</b>
IV site	IV site in RIGHT arm
Localizer	3 plane scout
Notes	<b>Precontrast MRA necessary before post contrast performed</b>

PLANE	SEQUENCE	FAT SAT	SLT/SP	FOV	NOTES
Axial	T1	Y	3-5 mm	20 cm	thyroid gland to skull base
Axial	2D and/or 3D TOF		<u>&lt; 1.5 or VOI</u>	24 cm	cover from thoracic inlet to skull base
Axial	3D TOF		VOI	24 cm	minimum coverage from aortic arch to floor of sella. Subclavian arteries 2 cm distal to the vertebral arteries.

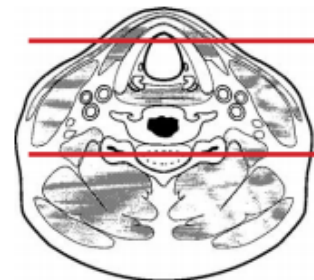
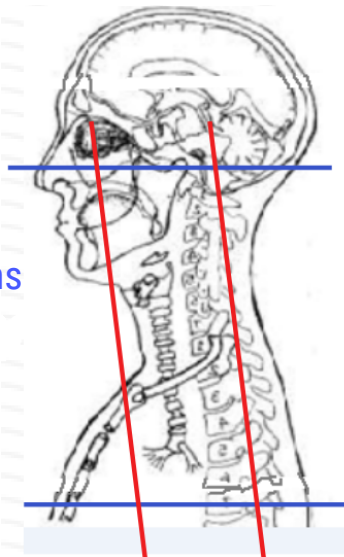
**\*\*Do vendor appropriate timing sequence prior to CE-MRA**

Interval  $\leq 0.75$  on recons

**Post processing**

- MIP right half of neck in R to L rotation
- MIP Left half of neck in R to L rotation
- MIP entire neck in R to L rotation
- MPR in sagittal and coronal plane. Send source images

Hard palate to include origins of CCA and Vert arteries



Any deviation from protocol MUST be Radiologist approved. Rad Director will be notified if this occurs without prior approval.