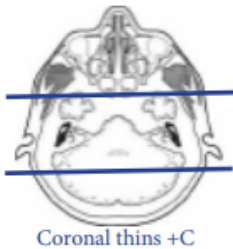


MRI CRANIAL/ FACIAL NERVE VII

| Indications | | Bell's palsy, peripheral facial nerve palsy, hemifacial spasm, facial weakness, 7th nerve abnormality, facial paralysis, perineural spread cancer along facial nerve | | | | |
|-------------|----------|---|--------------|---------|-------|--|
| Localizer | | 3 plane scout | | | | |
| PLANE | SEQUENCE | FAT SAT | MODE | SLT/SP | FOV | NOTES |
| Sagittal | T1 | | | 5 / 1.5 | 24 cm | |
| Axial | T1 | | | 5 / 1.5 | 24 cm | |
| Axial | T2 | | | 5 / 1.5 | 24 cm | |
| Axial | FLAIR | Y | | 5 / 1.5 | 24 cm | |
| Axial | DWI | | ADC MAP | 5 / 1.5 | 24 cm | B0 and B1000 |
| Axial | GRE, SWI | | | 5 / 1.5 | 24 cm | Perform your scanner equivalent |
| 3D Axial | T2 | | CiSS, FIESTA | 1.0 | 18 cm | Perform your scanner equivalent |
| Coronal | T1 | | | 3 / 1 | 18 cm | Parallel to brainstem include entire parotid gland |
| Axial | T1 | | | 3 / 1 | 18 cm | Parallel to brainstem include entire parotid gland |
| Axial + C | T1 | Y | | 3 / 1 | 18 cm | Parallel to brainstem include entire parotid gland |
| Coronal + C | T1 | Y | | 3 / 1 | 18 cm | Parallel to brainstem include entire parotid gland |
| Axial + C | T1 | Y | | 5 / 1.5 | 24 cm | through entire brain |



axial whole head

axial thins/3D

