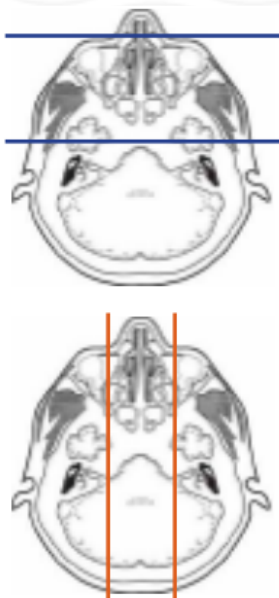


MRI BRAIN CRANIAL NERVE 1 WITHOUT & WITH CONTRAST

Indications				Loss of smell (anosmia), nasal/sinus encephalocele, floor of anterior intracranial fossa lesion		
Localizer				3 plane scout		
PLANE	SEQUENCE	FAT SAT	MODE	SLT/SP	FOV	NOTES
Sagittal	T1			5 / 1.5	24 cm	
Axial	T1			5 / 1.5	24 cm	
Axial	T2			5 / 1.5	24 cm	
Axial	FLAIR	Y		5 / 1.5	24 cm	
Axial	DWI		ADC MAP	5 / 1.5	24 cm	B 0 and B 1000
Axial	GRE, SWI			5 / 1.5	24 cm	perform your scanner equivalent
Axial	FIESTA			1.0	19 cm	angle images to orbits (perform your scanner equivalent)
Coronal	T2			3 / 1.0	16 cm	angled perpendicular to orbits
Coronal	T1			3 / 1.0	16 cm	
Sagittal	T1			3 / 1.0	16 cm	
Sagittal + C	T1			3 / 1.0	16 cm	
Coronal + C	T1			3 / 1.0	16 cm	
Axial + C	T1			5 / 1.5	24 cm	



Axial whole brain angled to AC-PC line

Small FOV axial FIESTA angled w/orbits

small FOV coronals perpendicular to orbits

**a similar protocol may be used for sinuses and nasal cavities. Call neuroradiologist for specifics

