

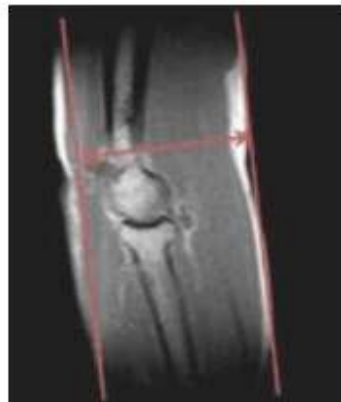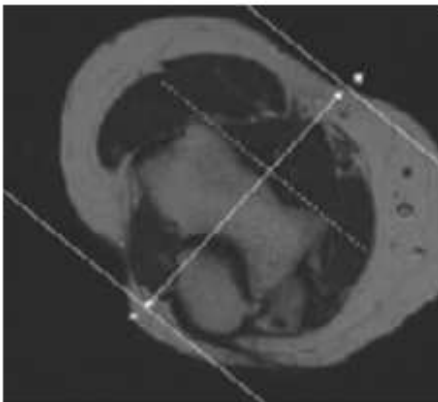
MRI ELBOW WITHOUT CONTRAST

Scan Range	Variable according to area of interest/ body part.				
FOV	Fits to patient/ body part.				
Position	Supine				
Localizer	3 plane scout localizer				
PLANE	SEQUENCE	FAT SAT	MODE	SLT/SP	FOV
Axial	T1				Small FOV
Axial	PD	Y			Small FOV
Coronal	PD	Y			14 - 16 cm
Coronal	STIR				14 - 16 cm
Sagittal	T2	Y			14 - 16 cm
ADD Coronal FABS	view for biceps	when suspected	for distal biceps	tendon pathology	
Coronal	PD	Y			FOV to visualize distal biceps tendon

POSITIONING AND PLANES

Patient Position - ROUTINE ELBOW

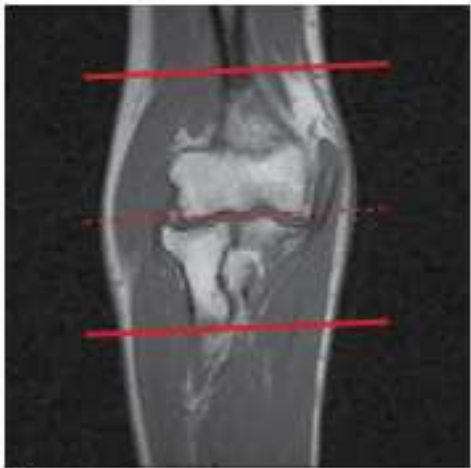- Supine (or if a large patient in the Superman position)
- Try to have elbow fully extended
- Try to have hand palm up
- Elevate elbow with a sponge to isocenter (if supine)
- Sponge and strap elbow in place if needed to reduce motion artifact



Coronal imaging

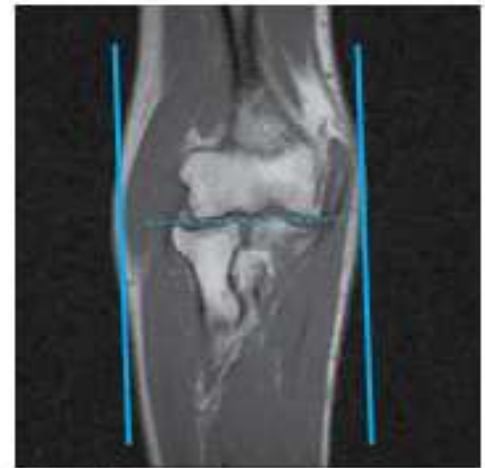
- Use axial LOC to angle parallel to anterior portions of the capitellum and trochlea (or parallel to humeral epicondyles)
- Use sagittal LOC to angle parallel to humerus/radius/ulnar plane, but closer to plane of radius if minimally flexed (if markedly flexed elbow, then angle between anterior humerus and the radius)
- Cover from back of the olecranon to at least 1 slice anterior to radial head

POSITIONING AND PLANES



Axial imaging

- Perpendicular to Coronal
- Use COR to angle parallel to elbow joint (parallel to capitellum and trochlea)
- Cover from 1 slice distal to radial tuberosity up as far as the slices go

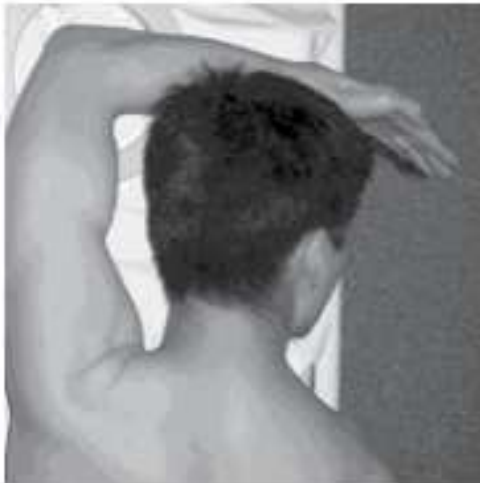

Sagittal imaging

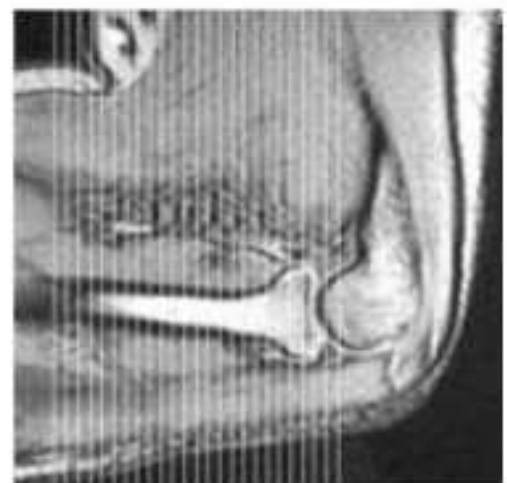
- Perpendicular to both Coronal and Axial sequences
- Cover 1 slice outside of both humeral epicondyles

FABS SEQUENCE POSITIONING AND PLANNING

- Reposition with arm abducted over head, flexed to 90 degrees (try to limit hyperflexion), and supinated (thumb up)
- Use shoulder coil and position around lower humerus, make sure to cover the radial tuberosity and cover up to approx. the mid humerus
- Axial LOC and then a 3 Plane LOC and get a good Sagittal LOC
- Angle Parallel to humeral shaft
- Obtain slices from outside of radial tuberosity and up to and including the humerus



Example patient positioning



FABS Coronal slice orientation from sagittal scout image