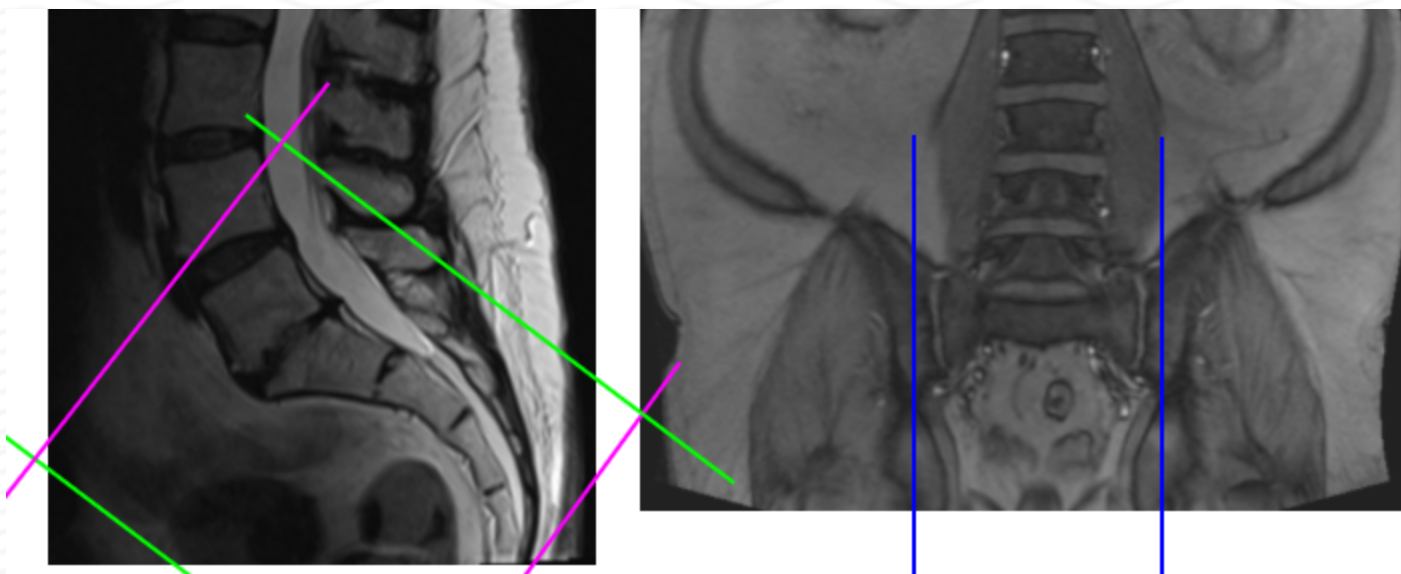


MRI SACRUM WITHOUT CONTRAST

Indications	Pain, trauma, ulcers , NOT for female reproductive or ovarian complaints.
Patient Position	Supine- feet internally rotated and patient made comfortable with sponges. Do not rotate if suspicion of femoral neck / hip fx.
FOV	Fits to patient/ body part
Localizer	3 plane scout localize
Notes	Include both sides of sacrum for the Sagittal sequences



PLANE	SEQUENCE	FAT SAT	MODE	SLT/SP	FOV	NOTES
Sagittal	T1			4 / 1	Approx 220 mm	
Axial oblique	T1			4 / 1	Approx 180 mm	
Axial oblique	T2			4 / 1	Approx 180 mm	
Sagittal	STIR TSE			4 / 1	Approx 220 mm	
Coronal oblique	STIR TSE			4 / 1	Approx 180 mm	
Coronal oblique	T1			4 / 1	Approx 180 mm	