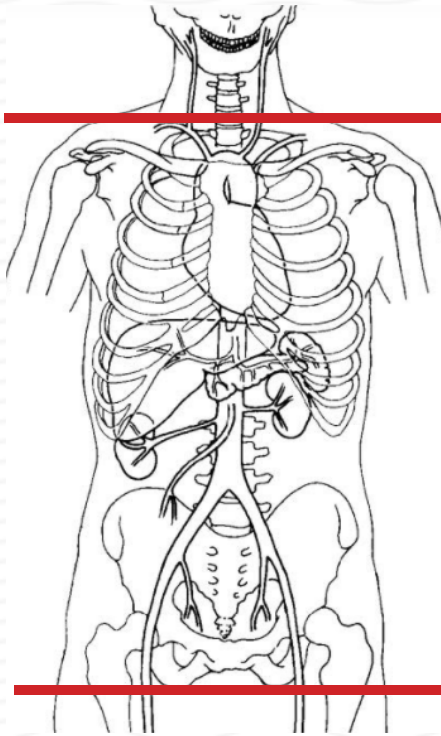


CT TRAUMA Chest/Abdomen/Pelvis (CAP) with IV Contrast



| | |
|----------------------|--|
| Indications | unspecified abdominal pain, trauma |
| Patient Position | Supine |
| Contrast | IV = 100 mL + oral if tolerated |
| Injection rate | 2.5 mL/sec minimum 22 g |
| Contrast timing | Portal venous phase 60 - 75 sec |
| Respiration | Breath- hold |
| Scan Parameters | lung apices through ischial tuberosity |
| Special instructions | <u>Trauma- use IV and oral IF patient can tolerate</u> |
| | Standard trauma & general A/P scans should NOT have delayed imaging without approval from Radiologist. Exception: high clinical suspicion for severe pelvic fx or bladder rupture. |
| NOTE | Do spine recons ONLY if ordered by the provider. Spine recons on trauma pts MUST be ordered as CT T spine & CT L spine. |

| PLANE | ALGORITHM | THICKNESS | DFOV | RECONS | NOTES |
|------------------------|-----------|-----------|-------------------|---------------------|---|
| Axial + C | Abdomen | 5.0 mm | pt largest + 4 cm | Portal venous phase | |
| Coronal + C | Abdomen | 5.0 mm | | X | |
| Sagittal + C | Abdomen | 5.0 mm | | X | |
| Sagittal & Coronal + C | BONE | 3.0 mm | | X | If ordered by the provider, T & L SPINE scans are to be reconstructed from the initial images. No need to rescan the patient. |

NOTES:



- Use at least 22g needle
- Follow GFR and Metformin protocols for contrast studies
- LMP on pts of child-bearing age
- Shield children when possible

Any deviation from protocol MUST be Radiologist approved. Rad Director will be notified if this occurs without prior approval.