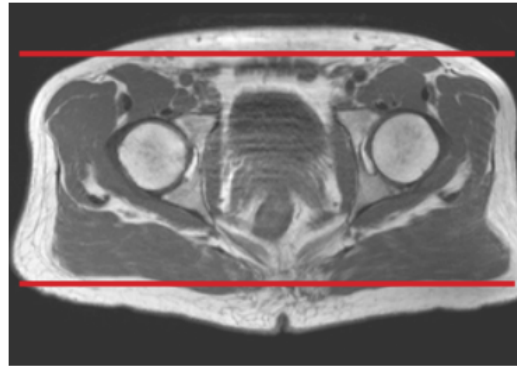
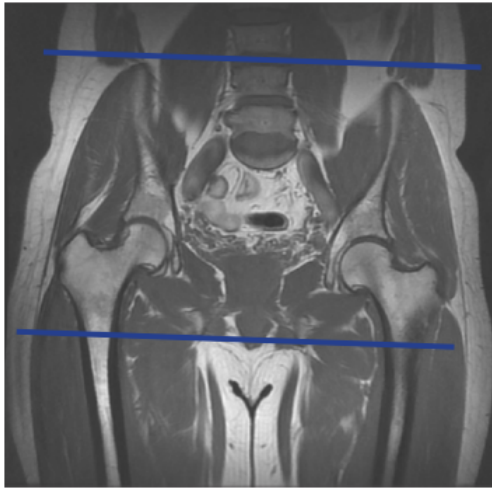


MRI PELVIS BONY WITHOUT & WITH CONTRAST

Patient Position	Supine- feet internally rotated and patient made comfortable with sponges. Do not rotate if suspicion of femoral neck / hip fx.
FOV	Fits to patient/ body part
Localizer	3 plane scout localize



PLANE	SEQUENCE	FAT SAT	SLT/SP	FOV	NOTES
Coronal	T1			Full FOV	Anterior to ilium to just past sacrum
Coronal	STIR			small FOV	Anterior to ilium to just past sacrum
Axial	T1	N		small FOV	just above iliac crest to level of greater trochanter
Axial	T1	Y		small FOV	just above iliac crest to level of greater trochanter
Axial	T2	Y		small FOV	just above iliac crest to level of greater trochanter
Sagittal	T2	Y		Full FOV	
Inject Contrast					
Axial + C	T1	Y		small FOV	just above iliac crest to level of greater trochanter
Coronal + C	T1	Y		Full FOV	Anterior to ilium to just past sacrum