Reviewed: Jan 2023
Updated: Sept 2020

South Georgia Radiology Associates

# MRI CRANIAL/ FACIAL NERVE VII

| | |
|---|---|
| **Indications** | **Bell's palsy, peripheral facial nerve palsy, hemifacial spasm, facial weakness, 7th nerve abnormality, facial paralysis, perineural spread cancer along facial nerve** |
| Localizer | 3 plane scout |

| PLANE | SEQUENCE | FAT SAT | MODE | SLT/SP | FOV | NOTES |
|---|---|---|---|---|---|---|
| Sagittal | T1 | | | 5 / 1.5 | 24 cm | |
| Axial | T1 | | | 5 / 1.5 | 24 cm | |
| Axial | T2 | | | 5 / 1.5 | 24 cm | |
| Axial | FLAIR | Y | | 5 / 1.5 | 24 cm | |
| Axial | DWI | | ADC MAP | 5 / 1.5 | 24 cm | B0 and B1000 |
| Axial | GRE, SWI | | | 5 / 1.5 | 24 cm | Perform your scanner equivilant |
| 3D Axial | T2 | | CiSS, FIESTA | 1.0 | 18 cm | Perform your scanner equivilant |
| Coronal | T1 | | | 3 / 1 | 18 cm | Parallel to brainstem include entire parotid gland |
| Axial | T1 | | | 3 / 1 | 18 cm | Parallel to brainstem include entire parotid gland |
| Axial + C | T1 | Y | | 3 / 1 | 18 cm | Parallel to brainstem include entire parotid gland |
| Coronal + C | T1 | Y | | 3 / 1 | 18 cm | Parallel to brainstem include entire parotid gland |
| Axial + C | T1 | Y | | 5 / 1.5 | 24 cm | through entire brain |

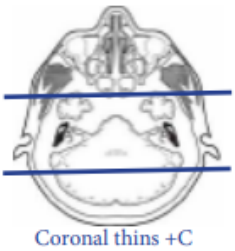


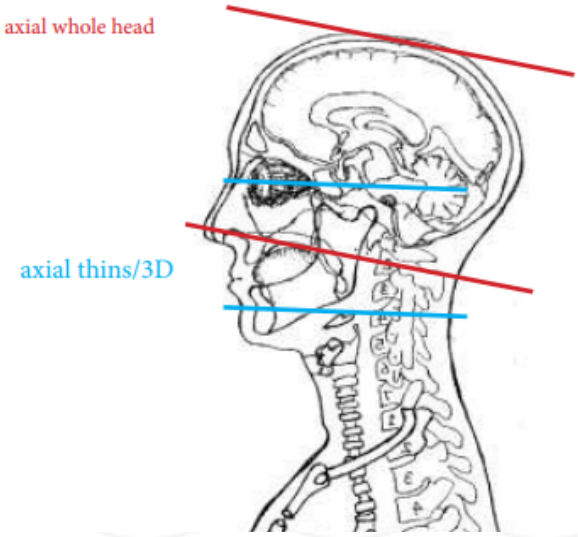


Any deviation from protocol MUST be Radiologist approved. Rad Director will be notified if this occurs without prior approval.