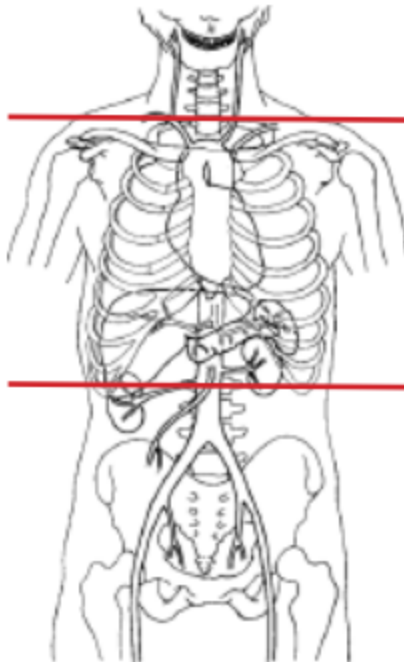


## CT CHEST HI RES (NON CONTRAST)



<b>Indications</b>	<b>Interstitial lung disease, pulmonary fibrosis</b>
Patient Position	Supine & Prone
Contrast	NONE
Respiration	Hold breath on inspiration
Scan Parameters	just above lung apices through adrenals

PLANE	ALGORITHM	THICKNESS	INTERVAL	DFOV	REFORMATS
<b>Axial - SUPINE</b>	Mediastinum	5.0 mm		pt largest + 4 cm	
Axial	Lung	5.0 mm			X
Sagittal	Mediastinum	5.0 mm			X
Coronal	Mediastinum	5.0 mm			X
Axial	MIP	8.0 mm	3.0 mm		X
Axial	Lung/ very sharp kernel	1.0 mm			1 mm for 2 consecutive cuts every 10 mm
<b>Axial - PRONE</b>	Lung/ very sharp kernel	1.0 mm			1 mm for 2 consecutive cuts every 10 mm

### NOTES:

- LMP on patients of child-bearing age
- Shield children when possible