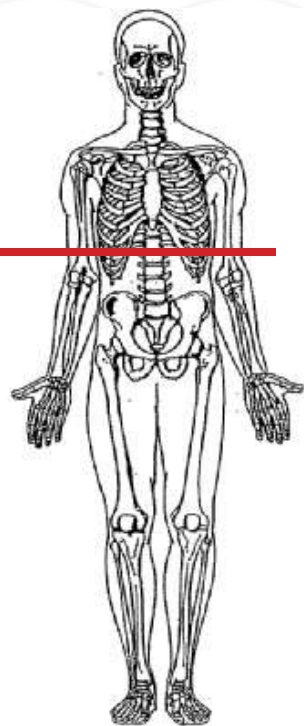


CTA LOWER EXTREMITY



Indications	vascular injuries in lower extremity trauma, including arterial laceration, transection, dissection, thrombotic occlusion, pseudoaneurysm, arteriovenous fistula
Patient position	Supine
Contrast	IV = 150 mL contrast
Injection rate	3.5 mL/sec minimum 20g, prefer 18g
Respiration	Breath hold on inspiration
Scan parameters	Aorta bifurcation through toes.
	ROI - descending aorta

PLANE	ALGORITHM	THICKNESS	DFOV		
Axial	Soft tissue	5.0 mm	pt largest + 4 cm	Bifurcation to toes	Pre-contrast
Axial + C	Soft tissue	3.0 mm		Bifurcation to below knees	2 scans ensure contrast to the feet
Axial + C	Soft tissue	3.0 mm		above knees to toes	2 scans ensure contrast to the feet
Coronal & Sagittal + C	Soft tissue	3.0 mm x 3.0 mm		entire leg	MPR reformat
Coronal & Sagittal + C	Soft tissue	8 mm x 5 mm		entire leg	MIPS
Coronal & Sagittal + C	Soft tissue	10 mm x 5 mm	<u>++OPTIONAL</u>	entire leg	MIPS only if requested by vascular surgeon

NOTES:

- LMP on pts of child-bearing age
- Shield children when possible
- Follow GFR and metformin protocol for contrast studies

Any deviation from protocol MUST be Radiologist approved. Rad Director will be notified if this occurs without prior approval.