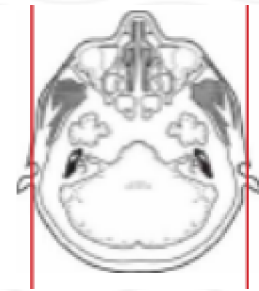
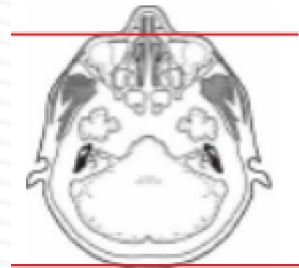
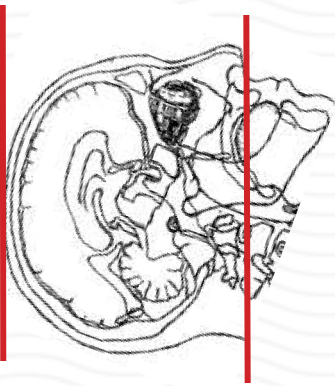


# CTV BRAIN

Indications	dural venous sinus thrombosis, vascular malformations, idiopathic intracranial hypertension
Patient position	Supine, IOML perpendicular to table (have patient tuck chin to chest)
Contrast	IV = 100 mL contrast
Injection rate	4 mL/sec with 45 sec delay to scan
Respiration	Breath hold
Scan parameters	Base of skull to vertex. Use head SFOV
NOTES	<u>MUST HAVE CT HEAD WITHOUT FIRST</u>
	<b>Must be ordered / billed as CTA but have notes to indicate reason for CTV</b>
	<b>Required to have 3D renderings of venous system</b>



PLANE	ALGORITHM	THICKNESS	DFOV	
Axial	Brain	5.0 mm	approx 220 mm	
Axial	Bone	5.0 mm		
Coronal & Sagittal	Brain	5.0 mm		Reformats
<b>INJECT CONTRAST</b>	<b>45 sec delay</b>	<b>BEFORE SCAN</b>		
Axial + C	Brain	1.25 mm		
Coronal & Sagittal + C	Brain	0.75 mm		Reformats
Axial, sag, cor + C	Brain	10 mm x 2mm		MIPS post contrast

**NOTES:**

- LMP on pts of child-bearing age
- Shield children when possible
- Follow GFR and metformin protocol for contrast studies

Any deviation from protocol MUST be Radiologist approved. Rad Director will be notified if this occurs without prior approval.