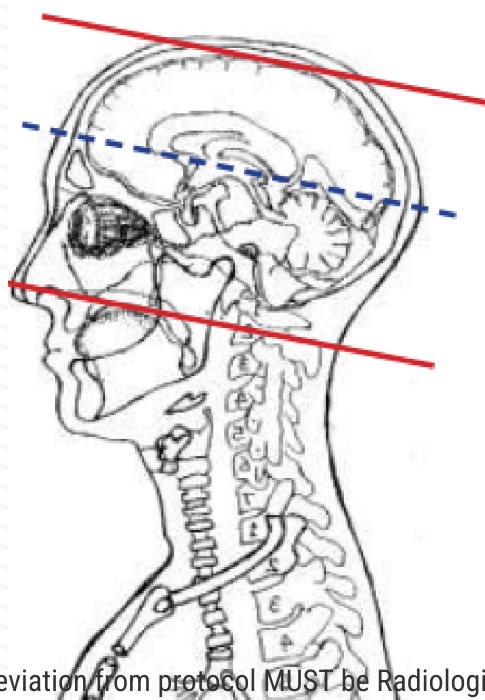


MRI BRAIN WITHOUT & WITH CONTRAST - Demyelinating MS

Indications				MS, optic neuritis, relapsing/remitting neurologic symptoms, younger patients, 50 y/o with atypical or unexplained neurologic symptoms		
Localizer				3 plane scout		
PLANE	SEQUENCE	FAT SAT	MODE	SLT/SP	FOV	NOTES
Sagittal	T1			5 / 1.5	24 cm	must cover entire brain
Axial	T1			5 / 1.5	24 cm	
Axial	T2			5 / 1.5	24 cm	
Axial	FLAIR	Y		5 / 1.5	24 cm	
Sagittal	FLAIR	Y		5 / 1.5	24 cm	
Axial	DWI		ADC MAP	5 / 1.5	24 cm	B 0 and B 1000 eADC when available
Axial	GRE, SWI			5 / 1.5	24 cm	perform your scanner equivalent
Coronal	3D T1			2	24 cm	must cover entire brain. DO NOT angle 3D
Coronal + C	3D T1			2	24 cm	must cover entire brain. DO NOT angle 3D
Sagittal + C	T1			5 / 1.5	24 cm	
Axial + C	T1			5 / 1.5	24 cm	



axials through entire brain vertex to foramen magnum
angled to anterior-posterior commissure (AC-PC)

Coronals through entire brain angled perpendicular to
AC-PC line (blue line)

Sagittal through entire brain

