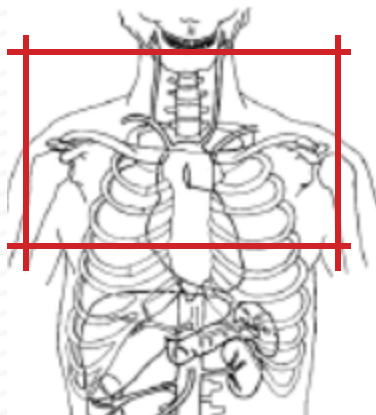


MRI CHEST WITHOUT & WITH CONTRAST : Thoracic Outlet



Indications	Thoracic outlet syndrome
Patient Position	Supine, arms adducted out of FOV
Contrast	Without and with
Respiration	Breath- hold should be encouraged
Scan Parameters	Center at aortic arch, body coil
Special notes	If unsure of scan parameters, check with Radiologist.
	PLACE IV in CONTRALATERAL extremity to symptoms

PLANE		Fat Sat	Mode	SLT/SP	FOV	NOTES
Coronal: HIGH RES	T1 WTSE				fit to patient	
Axial: HIGH RES	T1 WTSE				fit to patient	
Sagittal: HIGH RES	T1 WTSE				fit to patient	
Axial 3D	3D GRE				fit to patient	BREATH HOLD
Coronal 3D	3D MRA				fit to patient	BREATH HOLD
Test bolus: Timed off aortic arch						
Coronal + C	3D MRA				#1: at test bolus	BREATH HOLD
Coronal + C	3D MRA				#2: 12 sec delay	BREATH HOLD
Coronal + C	3D MRA				#3: 40 sec delay	BREATH HOLD
Axial + C	3D MRA					BREATH HOLD
CHANGE PT Position: Arms ABDUCTED external rotation						Repeat Variable scout
Coronal + C	3D MRA		2 acquisitions			BREATH HOLD
Coronal + C	3D MRA		isotropic voxel, reduce voxel size			BREATH HOLD
Axial + C	3D MRA - GRE		volume interpolated GRE			BREATH HOLD
Sagittal + C HIGH RES	T1 WTSE					for assessment of brachial plexus compression

Any deviation from protocol MUST be Radiologist approved. Rad Director will be notified if this occurs without prior approval.