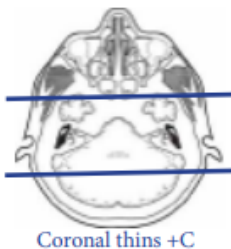


MRI CRANIAL/ FACIAL NERVE VII

Indications		Bell's palsy, peripheral facial nerve palsy, hemifacial spasm, facial weakness, 7th nerve abnormality, facial paralysis, perineural spread cancer along facial nerve				
Localizer		3 plane scout				
PLANE	SEQUENCE	FAT SAT	MODE	SLT/SP	FOV	NOTES
Sagittal	T1			5 / 1.5	24 cm	
Axial	T1			5 / 1.5	24 cm	
Axial	T2			5 / 1.5	24 cm	
Axial	FLAIR	Y		5 / 1.5	24 cm	
Axial	DWI		ADC MAP	5 / 1.5	24 cm	B0 and B1000
Axial	GRE, SWI			5 / 1.5	24 cm	Perform your scanner equivalent
3D Axial	T2		CISS, FIESTA	1.0	18 cm	Perform your scanner equivalent
Coronal	T1			3 / 1	18 cm	Parallel to brainstem include entire parotid gland
Axial	T1			3 / 1	18 cm	Parallel to brainstem include entire parotid gland
Axial + C	T1	Y		3 / 1	18 cm	Parallel to brainstem include entire parotid gland
Coronal + C	T1	Y		3 / 1	18 cm	Parallel to brainstem include entire parotid gland
Axial + C	T1	Y		5 / 1.5	24 cm	through entire brain



axial whole head

axial thins/3D

