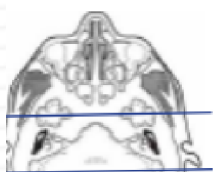
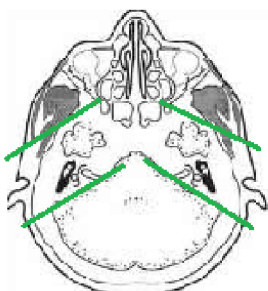


## MRI IAC / CRANIAL NERVE VIII

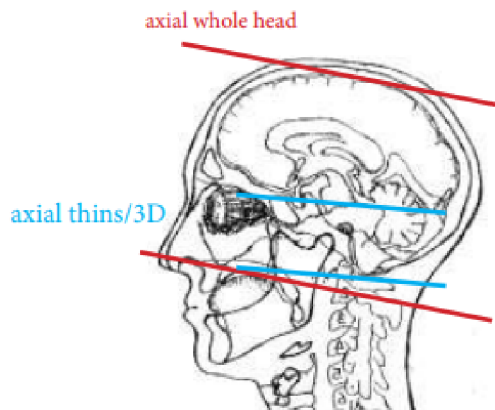
Indications				Sensorineural hearing loss, 8th nerve abnormality, hearing loss, vertigo, tinnitus, ear and /or mastoid infection		
Localizer				3 plane scout		
PLANE	SEQUENCE	FAT SAT	MODE	SLT/SP	FOV	NOTES
Sagittal	T1			5 / 1.5	24 cm	
Axial	T1			5 / 1.5	24 cm	
Axial	T2			5 / 1.5	24 cm	
Axial	FLAIR	Y		5 / 1.5	24 cm	
Axial	DWI		ADC Map		24 cm	B0 and B1000
Axial	GRE, SWI				24 cm	Perform your scanner equivalent
3D Axial	T2		CiSS FIESTA		24 cm	Perform your scanner equivalent
3D Parasagittal oblique	T2		CiSS FIESTA		18 cm	Perform your scanner equivalent oblique/ 2 scans
Coronal	T1			2.5 / 0.2	18 cm	Through IAC / temporal bones
<b>5 min DELAY</b>						<b>INJECT &amp; WAIT 5 minutes before scanning</b>
Axial + C	T1			2.5 / 0.2	18 cm	Through IAC / temporal bones
Coronal + C	T1			2.5 / 0.2	18 cm	Through IAC / temporal bones
Axial + C	T1			5 / 1.5	24 cm	through entire brain



Coronal thins +C



parasagittal oblique



axial whole head

axial thins/3D