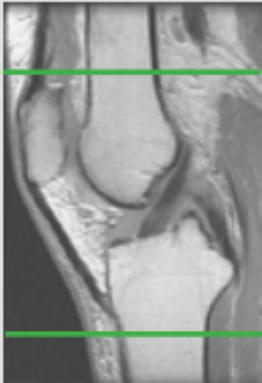


MRI KNEE ARTHROGRAM

Scan Range	Variable according to area of interest/ body part.
FOV	Fits to patient/ body part.
Position	SUPINE- Knee extended fully (as much as patient can tolerate). Minimize external/ internal rotation
Localizer	3 plane scout localizer

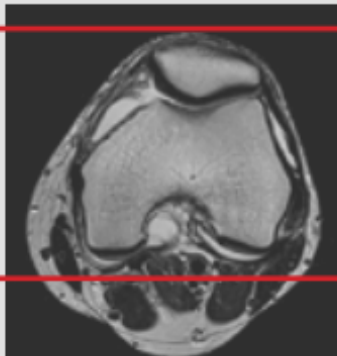
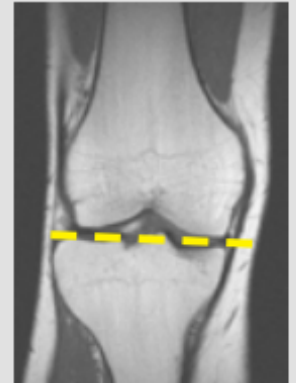
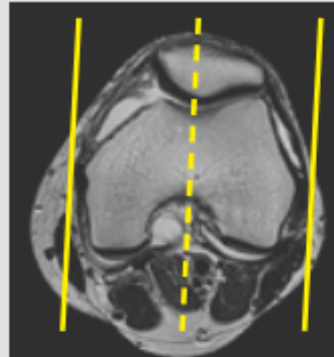
PLANE	SEQUENCE	FAT SAT	FOV	NOTES
Axial + C	T2	Y	14 - 16 cm	
Coronal + C	T1		16 cm	
Sagittal + C	T1	Y	16 cm	
Coronal + C	PD	Y	16 cm	
Sagittal + C	PD	Y	16 cm	

Image Plane Precriptions:



Axial imaging

- Cover from 2 Slices above the top of the Patella to the distal portion of the tibial tuberosity
- Perpendicular to the coronal and sagittal planes



Coronal imaging

- Anterior patella through fibular head
- Angle parallel to posterior femoral condyles on axial scout

Sagittal imaging

- Angle parallel to medial & lateral condyles
- Check positioning on coronal and angle parallel to tibial plateau
- Cover at least one slice past menisci on both sides